

## ORIGINAL ARTICLE

**Efficacy of Topical 0.03% Tacrolimus Dermatologic Ointment in Treatment of Vernal Keratoconjunctivitis**

Muhammad Adnan\*, Amena Masrur, Furqan Ahmed Khan, Ali Tayyab

**ABSTRACT**

**Objective:** To determine the efficacy of 0.03% Tacrolimus dermatologic ointment in the treatment of Vernal keratoconjunctivitis.

**Study Design:** Cross-sectional.

**Place and Duration of Study:** The study was conducted at Eye Donors Association Hospital, Wah Cantonment from August 2019 to January 2020.

**Materials and Methods:** 103 diagnosed patients of vernal keratoconjunctivitis, aged 3-16 years, were included in this study. They were treated with 0.03% Tacrolimus dermatologic ointment, applied in the inferior fornix once at night time, for a period of two months. In addition, these patients were also prescribed a topical anti-histamine (0.05 % ketotifen eye drops 3 times a day) and preservative free artificial tears for symptomatic relief. The patients were evaluated at 4 and 8 weeks after the initiation of treatment. At each follow up the clinical signs were assessed on a slit lamp biomicroscope by a single observer and recorded on a standardized grading sheet.

**Results:** Out of 103 patients, 66% were male and mean age was 9 years (range 3-16 years). The mean baseline scores showed a statistically significant decrease, with the exception of palpebral follicles & limbal Trantas dots after 8 weeks of treatment.

**Conclusion:** 0.03% Tacrolimus dermatologic ointment was found to be safe and effective in the treatment of vernal kerato-conjunctivitis.

**Key Words:** Steroid Sparing Agent, Tacrolimus, Vernal Keratoconjunctivitis.

**How to cite this:** Adnan M, Masrur A, Khan FA, Tayyab A. Efficacy of Topical 0.03% Tacrolimus Dermatologic Ointment in Treatment of Vernal Keratoconjunctivitis. *Life and Science*. 2021; 2(4): 138-143. doi: <http://doi.org/10.37185/LnS.1.1.142>

This work is licensed under a Creative Commons Attribution-NonCommercial 4.0 International license.

(<https://creativecommons.org/licenses/by-nc/4.0/>). Non-commercial uses of the work are permitted, provided the original work is properly cited.

**Introduction**

Vernal kerato-conjunctivitis (VKC) is an ocular inflammatory condition involving the ocular surface. Since both type I (Immunoglobulin E antibody (IgE) mediated) and type IV hypersensitivity (cell mediated or delayed hypersensitivity) reactions are implicated in its etiology, it tends to persist year-round with a seasonal exacerbation that is usually seen in the spring and summer.<sup>1</sup> Although almost always bilateral, the disease may be asymmetric in

nature with a higher prevalence seen in males.<sup>2</sup> The age group affected most commonly is between 3 and 16 years. However, the disease can start early and persists beyond the age of 16 years. A vast majority of patients, however experience some symptomatic relief around puberty.<sup>3</sup> Vernal-keratoconjunctivitis is characterized by the presence of papillae, conjunctival hyperemia, stringy mucoid discharge and, in severe cases, corneal involvement. The corneal signs include superficial epithelial keratopathy, pannus formation, keratoconus, shield ulcers and ultimately corneal scarring. The disease can thus have debilitating visual consequences.

The treatment of mild to moderate cases includes anti-histamines, mast cell stabilizers and non-steroidal anti-inflammatory eye drops. Severe cases often necessitate the use of topical steroids due to a higher risk of developing sight threatening

*Department of Ophthalmology*

*Islamabad Medical and Dental College, Islamabad*

*Correspondence:*

*Dr. Muhammad Adnan*

*Department of Ophthalmology*

*Islamabad Medical and Dental College,*

*Islamabad E-mail: madnank1984@gmail.com*

*Funding Source: NIL; Conflict of Interest: NIL*

*Received: Aug 23, 2020; Revised: Jun 21, 2021*

*Accepted: Sep 01, 2021*

complications secondary to the development of corneal ulcers and opacification. However, prolonged use of steroids in the management of vernal keratoconjunctivitis may be associated with complications inherent to these drugs and include cataract formation, ocular hypertension and steroid induced glaucoma.<sup>4,5</sup>

Tacrolimus is a 23-member cyclic macrolide lactone that suppresses the immune system via T-cell inhibition. Initially used to lower the risk of rejection after organ transplantation, it is now available in the form of an ointment for the treatment of atopic dermatitis. Off-label use of this skin ointment in a concentration of 0.03% has been reported in the literature for the management of various ocular surface inflammatory diseases including VKC.<sup>6,7</sup>

The purpose of this study was to assess the efficacy and safety of commercially available 0.03% Tacrolimus dermatologic ointment in the treatment of diagnosed patients of VKC.

### Materials and Methods

After obtaining approval from the institutional Review Board of Eye Donors Association Hospital, Wah Cantonment, Pakistan, 103 diagnosed patients of vernal keratoconjunctivitis presenting in the outpatient department, were recruited in the study. The board approved the off-label use of topical 0.03% Tacrolimus dermatologic ointment for Ophthalmic application. The duration of this study was 6 months from August 2019 to January 2020. A full disclosure of the study was made and informed consent obtained from the parents or legal guardians (since none of our patients were adults) of the participants of the study.

New or already diagnosed patients of vernal keratoconjunctivitis aged 3-16 years were included in the study. Patients younger than 3 years of age, those who had had ocular surgery or needed topical steroids to control VKC in the past 4 weeks, those with a history of ocular surface disease other than allergic conjunctivitis as well as those with a known history of sensitivity to ketotifen or tacrolimus were excluded from the study. At the time of enrollment in the study, all the patients underwent a routine ophthalmic examination using a slit lamp biomicroscope and all the presenting signs of VKC were entered in a standardized grading sheet. This grading sheet was based on the clinical

characteristics of VKC as described by Bonini et al.<sup>5</sup> This grading system is based on a 4 point-grade scale (0=none, 1=mild, 2=moderate and 3=severe) that takes into account the presence of conjunctival and corneal manifestations of the disease. The signs that were graded included conjunctival hyperemia and edema, presence of follicles, papillae, giant papillae, Tranta's dots superficial punctate keratitis and the formation of shield ulcer.

Patients who presented with palpebral papillae without any evidence of conjunctival hyperemia were classified as having grade 0 or quiescent disease. Patients exhibiting giant papillae with conjunctival hyperemia but no corneal involvement were put in grade 1 or mild disease. Development of superficial punctate keratitis in addition to the above signs was described as grade 2 or moderate disease while grade 3 or severe disease entailed the presence of limbal Horner-Tranta's spots or the formation of a shield ulcer.

Treatment with 0.03% Tacrolimus dermatologic ointment applied in the inferior fornix once at night time was initiated in all the patients who fulfilled the inclusion criteria. This treatment was in addition to conventional topical anti-histamine (0.05% ketotifen 3 times a day) and perseverative free artificial tears (used as required) prescribed for symptomatic relief. The patients were evaluated first after 4 weeks and then at 8 weeks, after the initiation of treatment. At each visit the severity of signs was evaluated by a single observer via slit lamp examination and recorded in the standardized grading sheet. The patients were also asked about any discomfort they experienced with the use of tacrolimus ointment. This was recorded in the proforma.

### Results

A total of 103 patients were enrolled in the study, of whom 68 (66%) were male and 35 (34%) were female. The mean age of the patients was 9.17 ( $\pm 2.6$ ) years (range: 3 to 16 years).

In this study seven (6.79%) patients had the palpebral type of VKC, while 96 (93.20%) presented with the mixed variety. The baseline composite sign scoring was done and it was found that 16 (15.5%) patients had mild VKC, 61 (59.2%) had moderate while 26 (25.24%) patients reported with the severe variety.

All the patients were examined using a slit lamp biomicroscope and the signs were noted in a

standardized scoring sheet (Table 1).

| Table 1: Signs noted at the time of recruitment in the study |           |            |
|--|-----------|------------|
| 1. Palpebral conjunctival signs                              | Frequency | Percentage |
| <b>a) Hyperemia</b>  |           |            |
| None   | 40        | 38.8%      |
| Dilatation of several vessels (1-4)                          | 41        | 39.8%      |
| Dilatation of many vessels (more than 4)                     | 22        | 21.4%      |
| Impossible to distinguish vessels                            | 0         | 0%         |
| <b>b) Edema</b>  |           |            |
| None   | 80        | 77.7%      |
| Slight edema   | 20        | 19.4%      |
| Thinner diffuse edema  | 03        | 2.9%       |
| Diffuse edema with opacity                                   | 0         | 0%         |
| <b>c) Follicles</b>  |           |            |
| None   | 98        | 95.1%      |
| 1-9 follicles  | 05        | 4.9%       |
| 10-19 follicles  | 0         | 0%         |
| More than 20 follicles                                       | 0         | 0%         |
| <b>d) Papillae</b>   |           |            |
| None   | 37        | 35.9%      |
| Papillae size 0.1-0.2mm                                      | 62        | 60.3%      |
| Papillae size 0.3-0.5mm                                      | 04        | 3.9%       |
| Papillae size 0.6 mm or more                                 | 0         | 0%         |
| <b>e) Giant Papillae</b>                                     |           |            |
| None   | 79        | 76.7%      |
| Flat papillae  | 14        | 13.6%      |
| Elevated papillae in <1/2 of upper palpebral conjunctiva     | 10        | 9.7%       |
| Elevated papillae in >1/2 of upper palpebral conjunctiva     | 0         | 0%         |
| <b>2. Bulbar conjunctival signs</b>                          |           |            |
| <b>a) Hyperemia</b>  |           |            |
| None   | 32        | 31.1%      |
| Dilatation of several vessels (1-4)                          | 47        | 45.6%      |
| Dilatation of many vessels (more than 4)                     | 22        | 21.45%     |
| Diffuse dilated blood vessels over entire bulbar conjunctiva | 02        | 1.9%       |
| <b>b) Edema</b>  |           |            |
| None   | 100       | 97.1%      |
| Localized  | 2         | 1.9%       |
| Thinner diffuse edema  | 1         | 1.0%       |
| Bullous edema  | 0         | 0%         |
| <b>3. Limbal signs</b>                                       |           |            |
| <b>a) Trantas dots</b>                                       |           |            |
| None   | 40        | 38.8%      |
| 1-4 dots   | 44        | 42.4%      |
| 5-8 dots   | 19        | 18.4%      |
| 9 or more dots   | 0         | 0%         |
| <b>b) Swelling</b>   |           |            |
| None   | 44        | 42.7%      |
| Found in <1/3 of limbal circumference                        | 37        | 35.9%      |
| Found in 1/3 to 2/3 of limbal circumference                  | 03        | 2.9%       |
| Found in 2/3 or more of limbal circumference                 | 03        | 2.9%       |

| 4. Corneal Epithelial Signs                |  |    |       |
|--|--|----|-------|
| None                                       |  | 75 | 72.8% |
| Superficial punctate keratitis             |  | 25 | 24.3% |
| Exfoliative superficial punctate keratitis |  | 03 | 2.9%  |
| Shield ulcer                               |  | 0  | 0%    |

The patients were evaluated at 4 and 8 weeks after the initiation of treatment with 0.03% Tacrolimus dermatologic ointment. Improvement in signs and symptoms was noted after 4 weeks of treatment. By 8 weeks after initiation of treatment all the patients were symptom free and the severity of a majority of the clinical signs had reduced considerably. This is shown in figure 1.

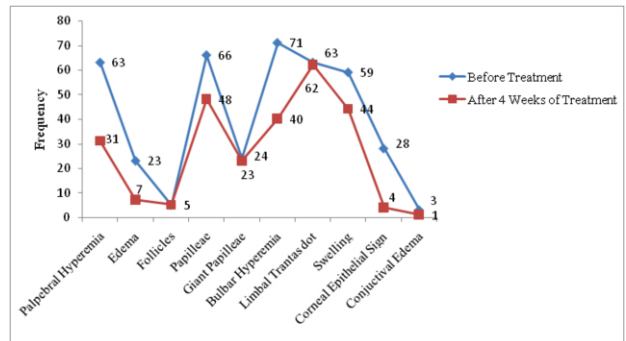


Fig 1: Comparison of sign and symptoms before treatment and after four weeks of treatment

The only signs that failed to resolve after 8 weeks were palpebral follicles and Horner-Tranta's dots. The mean score of signs before and after 8 weeks of treatment with 0.03% Tacrolimus dermatologic ointment is shown in table 2.

| Table 2: Mean score of signs before and after 8 weeks of treatment with 0.03% Tacrolimus dermatologic ointment |                        |               |          |            |          |
|--|------------------------|---------------|----------|------------|----------|
| Clinical sign  | At time of recruitment | After 4 Weeks | p- value | At 8 weeks | p- value |
| Palpebral Hyperemia  | 0.83±0.760             | 0.34±0.552    | 0.00     | 0.05±0.216 | 0.00     |
| Edema  | 0.25±0.499             | 0.08±0.303    | 0.00     | 0.01±0.099 | 0.00     |
| Follicles  | 0.5±0.216              | 0.05±0.216    | 1.00     | 0.04±0.294 | 0.32     |
| Papillae   | 0.78±0.546             | 0.50±0.558    | 0.00     | 0.20±0.428 | 0.00     |
| Giant Papillae   | 0.33±0.648             | 0.27±0.546    | 0.03     | 0.18±0.414 | 0.00     |
| Bulbar hyperemia   | 0.94±0.777             | 0.44±0.589    | 0.00     | 0.06±0.235 | 0.00     |
| Bulbar Edema   | 0.4±0.239              | 0.01±0.99     | 0.18     | 0.00±0.00  | 0.10     |
| LimbalTranta's dot   | .80±0.732              | 0.74±0.685    | 0.08     | 0.49±0.521 | 0.08     |
| LimbalSwelling   | 0.82±0.837             | 0.51±0.655    | 0.00     | 0.21±0.412 | 0.00     |
| Corneal Epithelial Signs   | 0.33±0.632             | 0.09±0.67     | 0.00     | 0.07±0.426 | 0.00     |

## Discussion

VKC is an ocular surface disease that usually persists all year-long, often requiring long-term therapy. Anti-allergic drugs often prove inadequate in the management of this disease especially when it exacerbates during the spring and summer months. Severe forms of the disease are often associated with sight threatening complications such as keratoconus and the formation of shield ulcers; prevention of these complications often necessitates the use of topical steroids. Prolonged use of topical steroids, however, is associated with a risk of iatrogenic cataract and glaucoma. This is especially worrisome since a majority of these patients belong to the pediatric age group.<sup>8</sup> Tacrolimus exhibits an immune modulatory effect by the inhibition of T cells which suppresses the release of cytokines and histamine that are responsible for the clinical manifestations of VKC. Results from preliminary studies tend to show that tacrolimus is effective in the treatment of patients of VKC especially those unresponsive to conventional medication.<sup>8,9,10</sup>

Our study demonstrated that 0.03% tacrolimus dermatologic ointment is effective in the management of patients of VKC. None of the patients was lost to follow up or had to be excluded from the study due to the development of severe clinical signs necessitating the use of topical steroids. In accordance with past research, most of our patients showed a marked alleviation of both the signs and symptoms of the disease without developing any significant adverse effects.<sup>8,9,10</sup> The signs and symptoms of most patients were relieved 4 weeks after initiation of tacrolimus ointment treatment (figure 1). The composite sign score significantly decreased from baseline values; however, the resolution of tarsal follicles and cobblestone papillae was delayed (figure 1). None of the patients in our study reported the development of any adverse effects with the use of tacrolimus ointment; however, the duration of follow up was not long enough for us to be able to draw a conclusion on its long-term effects.

Topical cyclosporine A is another drug that has been employed with varying success to alleviate the signs and symptoms of VKC as well as to reduce steroid dependence in the severe forms the disease. It is a naturally occurring cyclic polypeptide derived from

the fungus *Beauveria Nivea* and has immunosuppressant properties by virtue of its ability to inhibit the proliferation of T helper cells. In a study on the Turkish population it was reported by the authors that 0.05% topical cyclosporine eye drops proved effective and safe as an alternate therapy for severe cases of VKC refractory to conventional treatment.<sup>11</sup> However, another double blind, placebo controlled study by Daniell et al showed no statistically significant change in the symptoms, signs or drug scores of the patients were after 3 months of treatment.<sup>12</sup> Ohashi and colleagues explored the efficacy of 0.1% tacrolimus ointment for given for 4 weeks to 7 patients with VKC and compared the results with controls who were given a placebo.<sup>7</sup> The patients treated with tacrolimus ointment showed a considerable improvement in symptoms after 4 weeks as compared to those who were given a placebo. The concomitant use of topical or systemic antiallergic agents was allowed; this is comparable to our study in which topical ketotifen was prescribed for the provision of symptomatic relief. A retrospective consecutive case series reported by Miyazaki et al. concluded that 0.02% tacrolimus ointment used in the treatment of patients with refractory VKC was both safe and effective.<sup>13</sup> Moreover, no adverse effects were reported with up to 26 months of continuous treatment. The concentration of tacrolimus (0.02%) ointment employed by them is comparable to that employed in our study (0.03%). Kymionis et al. have reported that 0.03% tacrolimus ointment applied twice daily in the inferior fornix was efficacious in the treatment of giant papillary conjunctivitis refractory to conventional treatment.<sup>14</sup> A reduction in both the size and number of giant papillae was noted by them within 2 weeks of initiation of treatment with complete resolution of the disease seen after 4 weeks. These results are comparable to those seen in our patients. An open label study conducted on 30 Indian patients by Chatterjee and colleagues concluded that 0.03% tacrolimus ointment used in conjunction with 0.05% ketotifen eye drops was effective in the treatment of steroid refractory VKC.<sup>8</sup> The concentration of tacrolimus as well as the concomitant use of ketotifen and artificial tears is analogous to our study. The demographics of the study population

also closely match that of ours. However, in contrast to our study patients who were refractory to treatment with steroids were included in the study and the tacrolimus eye ointment was prescribed 3 times per day.

Pacharn and colleagues followed up diagnosed patients of VKC who were prescribed 0.1% tacrolimus eye ointment for a period of 3 years to determine the long-term response of the disease to topical tacrolimus.<sup>15</sup> They conclude that the disease remitted in a significant majority of the treated patients. In a case series reported by Tam et al, it was concluded that not only was topical tacrolimus safe and effective in the treatment of VKC, its initiation early in the disease could help prevent blinding complications.<sup>16</sup> These findings are similar to the conclusion drawn by us. The only signs that did not show a statistically significant improvement in our study population included follicles and limbal Tranta's dots. One explanation could be that these are representative of chronic degenerative changes and are hence persistent. However, a follow up duration of 8 weeks that was observed by us is too short for any elucidation of the long-term.

The therapeutic effects of tacrolimus in the resolution of these signs.

To the authors' knowledge this is the only study that has investigated the effect of topical 0.03% tacrolimus dermatologic ointment as a primary agent in the management of patients of VKC; a search of med-line indexed literature revealed that its role in only refractory cases has been deliberated by studies conducted in Pakistan. Since 0.03% topical tacrolimus was found to be effective and was not associated with any serious ophthalmic side effects, it could prove very useful in the management of all patients diagnosed with VKC. Its use should not be limited to just those who are refractory to conventional treatment. In fact, early treatment with tacrolimus ointment could be paramount in the prevention of the visually debilitating complications of the disease. We also recommend the ointment for ocular use as this would translate into ease of use and hence better compliance on the patients' part. A small sample size, absence of randomization and a control group were the main limitations of the current study. It was not considered whether a patient had presented for the first time with VKC

symptoms or was refractory to conventional topical medications including prior steroid use. The patients were not followed up for a duration long enough to know the possible adverse effects of tacrolimus, or the persistence of its beneficial effect after discontinuation of therapy.

## Conclusion

It can be inferred that the off-label use of topical 0.03% Tacrolimus dermatologic ointment is a safe and effective option in the treatment of patients with VKC. Further studies are however required to determine the long term systemic and ocular safety of the drug.

## REFERENCES

1. Tabbara AK, El-Asrar A. Immunopathogenesis of ocular allergy. *Progress in allergy and clinical immunology*. Seattle: Hogrefe & Huber. 1997. p. 381–5.
2. Fiorentini SF, Khurram D. Therapeutic effects of topical 0.03% Tacrolimus ointment in children with refractory vernal keratoconjunctivitis in Middle East. *Saudi J Ophthalmol*. 2019; 33: 117-20.
3. Sacchetti M, Lambiase A, Moretti C, Mantelli F, Bonini S. Sex hormones in allergic conjunctivitis: altered levels of circulating androgens and estrogens in children and adolescents with vernal keratoconjunctivitis. *J Immunol Res*. 2015; 2015: 945317
4. Leonardi A. Vernal keratoconjunctivitis: pathogenesis and treatment. *Prog Retin Eye Res*. 2002; 21: 319-39.
5. Bonini S, Bonini S, Lambiase A, Marchi S, Pasqualetti P, Zuccaro O, et al. Vernal keratoconjunctivitis revisited: a case series of 195 patients with long-term followup. *Ophthalmology*. 2000; 107: 1157-63.
6. Joseph MA, Kaufman HE, Insler M. Topical tacrolimus ointment for treatment of refractory anterior segment inflammatory disorders. *Cornea*. 2005; 24: 417-20.
7. Ohashi Y, Ebihara N, Fujishima H, Fukushima A, Kumagai N, Nakagawa Y, et al. A randomized, placebo-controlled clinical trial of tacrolimus ophthalmic suspension 0.1% in severe allergic conjunctivitis. *J Ocul Pharmacol Ther*. 2010; 26: 165-74.
8. Chatterjee S, Agrawal D. Tacrolimus in Corticosteroid-Refractory Vernal Keratoconjunctivitis. *Cornea*. 2016; 35: 1444-8.
9. Zhai J, Gu J, Yuan J, Chen J. Tacrolimus in the treatment of ocular diseases. *BioDrugs*. 2011; 25: 89-103.
10. Sengoku T, Sakuma S, Satoh S, Kishi S, Ogawa T, Ohkubo Y, et al. Effect of FK506 eye drops on late and delayed-type responses in ocular allergy models. *Clin Exp Allergy*. 2003; 33: 1555-60.
11. Yücel OE, Ulus ND. Efficacy and safety of topical cyclosporine A 0.05% in vernal keratoconjunctivitis. *Singapore Med J*. 2016; 57: 507-10.
12. Daniell M, Constantinou M, Vu HT, Taylor HR. Randomised controlled trial of topical ciclosporin A in steroid dependent

- allergic conjunctivitis. *Br J Ophthalmol.* 2006;90:461-4.
13. Miyazaki D, Tominaga T, Kakimaru-Hasegawa A, Nagata Y, Hasegawa J, Inoue Y. Therapeutic effects of tacrolimus ointment for refractory ocular surface inflammatory diseases. *Ophthalmology.* 2008;115:988-92.
  14. Kymionis GD, Goldman D, Ide T, Yoo SH. Tacrolimus ointment 0.03% in the eye for treatment of giant papillary conjunctivitis. *Cornea.* 2008;27:228-9.
  15. Pacharn P, Visitsunthorn N, Jirapongsananuru KO, Vichyanond, P. Vernal Keratoconjunctivitis (vkc) Treated with 0.1% Fk-506 Ophthalmic Ointment: Result of A Three Years Follow-up. *J allergclinimmunol.* 2007;119:536-7.
  16. Tam PM, Young AL, Cheng LL, Lam PT. Topical tacrolimus 0.03% monotherapy for vernal keratoconjunctivitis--case series. *Br J Ophthalmol.* 2010;94:1405-6.
-