

ORIGINAL ARTICLE

Navigating Vascular Access Challenges in End-Stage Renal Disease: A Comprehensive Study of Ultrasonographic Guided Tunneled Hemodialysis Catheters

Mirza Zeeshan Sikandar^{1*}, Maryam Javed², Muhammad Azhar Waheed³, Azhar Ali Khan³, Hamna Amjad³, Sheikh Muhammad Hassaan Moeen³

ABSTRACT

Objective: This study aims to assess the efficacy of Ultrasonographic Guided Tunneled Hemodialysis Catheters in patients with ESRD. The primary objectives include assessing catheter placement success, blood flow adequacy, and the prevention of catheter related blood stream infections.

Study Design: A cross-sectional study.

Place and Duration of Study: The study was conducted at the Department of Nephrology, Central Park Medical College and Hospital Lahore, Pakistan from December 2022 to May 2023.

Methods: In this study, enrolled 40 end stage renal disease patients aged 20 to 60 years. Tunneled Hemodialysis Catheters (THCs) were inserted under ultrasonographic guidance, predominantly in the right internal jugular vein. Demographic and clinical data were recorded, and blood flow was assessed for dialysis adequacy. The study followed STROBE guidelines and obtained ethical clearance.

Results: Of the 40 patients, 50% were male, 85% had hypertension, and 87.5% had diabetes. Ultrasonography guided Tunneled Hemodialysis Catheters were predominantly placed in the right internal jugular vein (55%) with overall success rate of 100 percent. Mean blood flow was 317 ml/minute, and patients had a history of 4.29 ± 1.18 previous catheters. No CRBSIs were reported within the study period.

Conclusion: Ultrasonographic guided Tunneled Hemodialysis Catheters demonstrated effective placement, adequate blood flow, and a notable absence of catheter related blood stream infections. The study contributes valuable insights into the role of Tunneled Hemodialysis Catheters in ESRD care, emphasizing their significance as an interim solution while awaiting arteriovenous fistula maturation.

Keywords: Chronic Kidney Disease, Dialysis, End Stage Renal Disease, Patient Outcome Assessment, Vascular Catheters.

How to cite this: Sikandar MZ, Javed M, Waheed MA, Khan AA, Amjad H, Moeen SMH. Navigating Vascular Access Challenges in End-Stage Renal Disease: A Comprehensive Study of Ultrasonographic Guided Tunneled Hemodialysis Catheters. *Life and Science*. 2024; 5(4): 477-481. doi: <http://doi.org/10.37185/LnS.1.1.541>

This work is licensed under a Creative Commons Attribution-NonCommercial 4.0 International license.

(<https://creativecommons.org/licenses/by-nc/4.0/>). Non-commercial uses of the work are permitted, provided the original work is properly cited.

Introduction

Chronic kidney disease (CKD) has emerged as a prevalent global health concern, with a

¹Department of Nephrology

Central Park Medical College Lahore, Pakistan

²Department of Nephrology

Sheikh Zaid Hospital Lahore, Pakistan

³Department of Nephrology

Choudhary Muhammad Akram Teaching Hospital Lahore,

Pakistan

Correspondence:

Dr. Mirza Zeeshan Sikandar

Department of Nephrology

Central Park Medical College Lahore, Pakistan

E-mail: m.zee.shan@hotmail.com

Received: Dec 01, 2023; 1st Revision Received: Feb 20, 2024

2nd Revision Received: Jul 17, 2024; Accepted: Aug 05, 2024

consequential increase in the incidence of End-Stage Renal Disease (ESRD).^{1,2} This escalating burden presents a myriad of challenges, particularly in the establishment of effective vascular access for hemodialysis. Among the complications that contribute significantly to mortality rates in this vulnerable population, Catheter Related Bloodstream Infections (CRBSIs) stand out as a formidable adversary.³

The landscape of renal replacement therapy constantly evolves, and within this dynamic milieu, THCs have become indispensable in bridging the gap between the immediate need for hemodialysis and the establishment of a more permanent vascular

access solution.⁴ In the intricate landscape of renal care, Tunneled Hemodialysis Catheters (THCs) have garnered attention as a pragmatic solution, serving as a viable option for short to intermediate term vascular access. As we navigate the complexities of renal care, it becomes evident that the utilization of THCs is not merely a stopgap measure; rather, it represents a strategic intervention to address the time sensitive demands of patients with ESRD. THCs, designed with the consideration of these challenges, emerge as a vital conduit in maintaining the continuity of hemodialysis, thereby preventing disruptions in the therapeutic continuum.^{5,6} THCs play a crucial role, especially when patients are in the interim period, awaiting the maturation of an Arteriovenous Fistula (AVF), or when AVF placement is contraindicated for various reasons.⁷

This intricate interplay between the rising incidence of ESRD, the imperative need for vascular access, and the prevalence of CRBSIs underscores the critical importance of exploring and understanding the role of Tunneled Hemodialysis Catheters in renal care. In this manuscript, we delve into the multifaceted dimensions of THCs, dissecting their efficacy, challenges, and implications in the context of improving patient outcomes and mitigating the risks associated with vascular access complications. Through a comprehensive examination of pertinent parameters and rigorous testing methodologies, our study aims to shed light on the nuanced intricacies of THCs, assessing the success rate, blood flow and followed catheter related blood stream infections (CRBSIs).

Methods

A cross sectional study was conducted at the Department of Nephrology, Central Park Medical College and Hospital Lahore, Pakistan under STROBE guidelines from December 2022 to May 2023 for the assessment of outcomes of ultrasonographic guided tunneled hemodialysis catheter in patients of end stage renal disease. Under the guidelines of Helsinki declaration, ethical letter was obtained from Institutional Review Board of the college vide letter no: CPMC/IRB-No/2237 held on 30th November 2022. In this study 40 patients of ESRD with age range of 20 to 60 years of age were recruited after obtaining prior written informed consent from all the

study participants. But patients of acute kidney injury or those patients who cause of ESRD has not yet established were excluded in this study.

Detailed demographic and personal history were recorded in the study Performa including age, gender, history of diabetes, hypertension, number of temporary lines, AVF and its maturation, history of infection followed by tunneled catheter were recorded. Similarly, after tunneled catheter every patient went through chest radiograph anteroposterior view for confirmation of the place of catheter.

For tunneled catheter patients was made lying supine comfortably on procedure bed and under the guidance of portable ultrasound venous access was assessed prioritizing the lines as Right internal jugular vein, right femoral vein, left internal jugular vein and left femoral vein. After assessment and finalization of the site for tunneled catheter, that particular area was exposed and marking was made as per size of the catheter and additional local anesthesia was given at the site of the catheter insertion. Subcutaneous plane was identified and via mosquito artery a tunnel was made and guide wire was passed in the subsequent chosen major venous vessel followed dilatation by trocars and eventually passing the catheter and taking the guidewire out. Before stitching and final placing of the catheter flow was assessed and minimal flow of 300 ml/minute was set as standard and later were closed with heparinized caps to prevent risk of thromboembolism.

Statistical Analysis

Anonymized data was entered into Microsoft Excel version 2019 and was dully compared and assessed for any errors and omissions and after cross verifying the data, it was imported into Statistical Package for Social Sciences ver. 26 where qualitative variables were computed in terms of frequencies and percentages and was presented as bar charts and graphs. Mean and standard deviation for age, blood and previous number of catheters were recorded and significance was assessed using independent sample t test and for all the qualitative variables chi square test and correlation was employed. A *P* value less than 0.05 was regarded as significant.

Table-1: Explanation of Gender and Chronic Diseases in Study Population

| Study Parameters | Sub-Groups | n | Parentage % |
|------------------|------------|----|-------------|
| Gender | Male | 20 | 50 |
| | Female | 20 | 50 |
| Hypertension | Yes | 34 | 85 |
| | No | 06 | 15 |
| Diabetic | Yes | 35 | 87.5 |
| | No | 05 | 12.5 |

Table-2. Assessment of Blood Flow & Previous Catheters by one sample t test

| Variables | Mean + St. Dev | t-value | P-value |
|--------------------------|----------------|---------|---------|
| Blood Flow | 317 ± 7.17 | 202.657 | 0.001* |
| No of Previous Catheters | 4.29 ± 1.18 | 16.514 | 0.001* |

Results

A total of 40 patients of ESRD were recruited in this study with mean age of 49.33 + 14.47 years. In these 40 patients, 20 patients were males (50%) and 20 were females (50%) with equal distribution. Among these 34 were hypertensive (85%) while 6 (15%) were non-hypertensive. Similarly, among these 35 were diabetic (87.5%) while 5 patients (12.5%) were non-diabetic. Table-1.

Ultrasonography guided tunneled catheters were inserted to all the patients with predominant sit of right internal jugular vein (n=22) were 55%, left internal jugular catheters were (n=14) were 35% while rest of the catheters 10% (n=4) were inserted into right femoral vein with P value of 0.203 as explained in figure.1 with overall success rate of 100 percent.

Blood flow was assessed in all the catheters, which showed mean blood flow of 317 ± 7.17 ml per minute, with P value of 0.001 suggestive of good and

adequate blood flow for dialysis on appliance of one sample t test as explained in table 2. Previous number of temporary catheters were also noted by employing independent sample t test; 4.29 ± 1.18 with range of 2 to 6 and P value of 0.002 suggesting that before tunneled catheters patients had enough number of double lumens as explained in table-2. Position of catheter was confirmed by obtaining chest x ray right after the procedure which showed acceptable position in all right and left internal jugular vein catheters.

Assessment for catheter related blood stream infection (CRBSI) was made, and no CRBSI was noted in first 3 days, in first 10 days and in first 21 days. Out of all the catheters 4 were done under fluoroscopy to ensure the tip positioning and all were left sided. All the catheters were in adequate functioning and antibiotics were administered to all the patients which resulted in no CRBSI as explained above.

Discussion

The rising prevalence of Chronic Kidney Disease (CKD) on a global scale has given way to a surge in the incidence of End Stage Renal Disease (ESRD), posing substantial challenges in establishing effective vascular access for hemodialysis. In the intricate landscape of renal care, Catheter Related Bloodstream Infections (CRBSIs) have emerged as a significant contributor to mortality rates among individuals grappling with ESRD. Within this context, Tunneled Hemodialysis Catheters (THCs) have become indispensable, providing a crucial bridge for patients awaiting the maturation of an

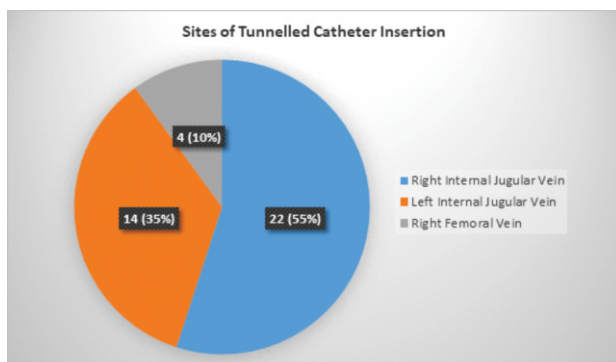


Fig.1: Distribution of Tunnelled Catheters based on their sites

Arteriovenous Fistula (AVF) or those who, for various reasons, cannot undergo AVF placement.

Our study on the outcomes of ultrasonographic guided tunneled hemodialysis catheters in End Stage Renal Disease (ESRD) patients provides crucial insights into the efficacy and safety of this vascular access modality. To deepen our understanding, it is imperative to contextualize our findings in relation to previous research in the field.

In alignment with our results, prior studies have consistently recognized the importance of Tunneled Hemodialysis Catheters (THCs) in providing short term to intermediate term vascular access for ESRD patients awaiting the maturation of an Arteriovenous Fistula (AVF) or when AVF placement is contraindicated. Our emphasis on ultrasonographic guidance for catheter insertion echoes findings from studies emphasizing the significance of imaging techniques in ensuring precise placement, minimizing complications, and optimizing catheter function.⁸⁻¹⁰

Comparing our demographic data, the distribution of gender, and the prevalence of comorbidities like hypertension and diabetes align with the broader trends observed in ESRD populations across various studies.¹¹⁻¹³ This consistency reinforces the universality of these challenges in renal care and emphasizes the need for tailored vascular access solutions. Our study's preference for the right internal jugular vein for catheter insertion resonates with the existing literature, highlighting the practical advantages associated with this approach, such as reduced infection risk and enhanced procedural safety.^{14,15} The mean blood flow of 317 ml per minute aligns with the standards for adequate dialysis, demonstrating the functionality of the tunneled catheters in facilitating effective hemodialysis.¹⁶

The absence of Catheter Related Bloodstream Infections (CRBSI) in our study during critical post catheterization periods is a notable finding. This aligns with research advocating for meticulous aseptic techniques and antibiotic prophylaxis to minimize infection risks.¹⁷ The use of fluoroscopy in selected cases for tip positioning is consistent with studies emphasizing the importance of imaging modalities in ensuring catheter placement accuracy.¹⁸ While our study contributes valuable

insights, it is essential to acknowledge its limitations. The sample size, although adequate for a cross-sectional study, may limit the generalizability of our findings. Additionally, the absence of a comparative group, such as patients with different vascular access modalities, restricts our ability to draw direct comparisons.

Conclusion

Tunneled Hemodialysis Catheters (THCs) offer a crucial bridge for patients awaiting Arteriovenous Fistula (AVF) maturation or those for whom AVF placement is not immediately feasible. The preference for the right internal jugular vein aligns with best practices, minimizing the risk of infections and associated coagulation and thrombus formation. As the landscape of renal replacement therapy continues to evolve, our study adds to the ongoing discourse in nephrology, providing a basis for further research and advancements in vascular access modalities.

Acknowledgment: None.

Conflict of Interest: The authors declare no conflict of interest.

Grant Support and Financial Disclosure: None.

REFERENCES

1. Lawson JH, Niklason LE, Roy-Chaudhury P. Challenges and novel therapies for vascular access in haemodialysis. *Nature Reviews Nephrology*. 2020; 16: 586-602. doi: 10.1038/s41581-020-0333-2
2. Agarwal AK, Haddad NJ, Vachharajani TJ, Asif A. Innovations in vascular access for hemodialysis. *Kidney international*. 2019; 95: 1053-63. doi: 10.1016/j.kint.2018.11.046
3. Yeo WS, Ng QX. Disruptive technological advances in vascular access for dialysis: an overview. *Pediatric Nephrology*. 2018; 33: 2221-6. doi: 10.1007/s00467-017-3853-7
4. Dawoud D, Lok CE, Waheed U. Recent advances in arteriovenous access creation for hemodialysis: new horizons in dialysis vascular access. *Advances in Chronic Kidney Disease*. 2020; 27: 191-8. doi: 10.1053/j.ackd.2020.02.002
5. Hegde AS, Kshirsagar AV, Roy-Chaudhury P. Dialysis access: at the intersection of policy, innovation, and clinical care. *Advances in Chronic Kidney Disease*. 2020; 27: 263-7. doi: 10.1053/j.ackd.2020.04.002

6. Vachharajani TJ, Taliercio JJ, Anvari E. New Devices and Technologies for Hemodialysis Vascular Access: A Review. *American Journal of Kidney Diseases*. 2021; 78: 116-24. doi: 10.1053/j.ajkd.2020.11.027
7. Xu T, Zeng N, Li N. Assessment of dysfunctional tunneled hemodialysis catheters and outcome of endovascular salvage techniques: a simple solution to a complex problem. *Frontiers in Cardiovascular Medicine*. 2023; 10: 1063450. doi: 10.3389/fcvm.2023.1063450
8. Shirasu T, Yodsanit N, Li J, Huang Y, Xie X, Tang R, et al. Neointima abating and endothelium preserving—An adventitia-localized nanof ormulation to inhibit the epigenetic writer DOT1L. *Biomaterials*. 2023; 301: 122245. doi: 10.1016/j.biomaterials.2023.122245
9. DePietro DM, Trerotola SO. Choosing the right treatment for the right lesion, Part II: a narrative review of drug-coated balloon angioplasty and its evolving role in dialysis access maintenance. *Cardiovascular Diagnosis and Therapy*. 2023; 13: 233-59. doi: 10.21037/cdt-22-497
10. Rabindranath KS, Kumar E, Shail R, Vaux E. Use of real-time ultrasound guidance for the placement of hemodialysis catheters: a systematic review and meta-analysis of randomized controlled trials. *American Journal of Kidney Diseases*. 2011; 58: 964-70. doi: 10.1053/j.ajkd.2011.07.025.
11. Chalmers N. Imaging in the Dialysis Patient: The Role of Vascular Radiology in Hemodialysis Access. *In Seminars in Dialysis*. 2002; 15: 259-68. doi: 10.1046/j.1525-139x.2002.00068.x
12. Saran R, Robinson B, Abbott KC, Agodoa LY, Bhav e N, Bragg-Gresham J, et al. US renal data system 2017 annual data report: epidemiology of kidney disease in the United States. *American Journal of Kidney Diseases*. 2018; 71: A7.
13. Pippias M, Jager KJ, Kramer A, Leivestad T, Sánchez MB, Caskey FJ, et al. The changing trends and outcomes in renal replacement therapy: data from the ERA-EDTA Registry. *Nephrology Dialysis Transplantation*. 2016; 31: 831-41. doi: 10.1093/ndt/gfv327
14. Lok CE, Mokrzycki MH. Prevention and management of catheter-related infection in hemodialysis patients. *Kidney International*. 2017; 92: 246-59. doi: 10.1038/ki.2010.471
15. Vanholder R, Davenport A, Hannedouche T, Kooman J, Kribben A, Lameire N, et al. Reimbursement of dialysis: a comparison of seven countries. *Journal of the American Society of Nephrology*. 2012; 23: 1291-8. doi: 10.1681/ASN.2011111094
16. Gompelman M, Causevic E, Bleeker-Rovers CP, Wanten GJA. Catheter-related bloodstream infection management in patients receiving home parenteral nutrition: An observational cohort study. *Clinical Nutrition ESPEN*. 2022; 50: 155-61. doi: 10.1016/j.clnesp.2022.06.003.
17. Oliver MJ, Callery SM, Thorpe KE, Schwab SJ, Churchill DN. Risk of bacteremia from temporary hemodialysis catheters by site of insertion and duration of use: a prospective study. *Kidney International*. 2000; 58: 2543-5. doi: 10.1046/j.1523-1755.2000.00439.x
18. Xu BJ, Duszak R Jr, McGinnis RS, Stanfill JG, O'Rear J, An AQ. Increased fluoroscopy time for central venous catheter placement by radiology residents versus staff radiologists. *Journal of the American College of Radiology*. 2013; 10: 518-22. doi: 10.1016/j.jacr.2012.12.023.

Authors Contribution

MZS: Idea conception, study designing, data collection, data analysis, results and interpretation, manuscript writing and proofreading

MJ: Idea conception, study designing, data collection, data analysis, results and interpretation, manuscript writing and proofreading

MAW: Idea conception, study designing, data collection, data analysis, results and interpretation, manuscript writing and proofreading

AAK: Idea conception, study designing, data collection, data analysis, results and interpretation, manuscript writing and proofreading

HA: Study designing, data collection, data analysis, results and interpretation, manuscript writing and proofreading

SMHM: Study designing, data collection, data analysis, results and interpretation, manuscript writing and proofreading