

## CASE REPORT

### Multidisciplinary Strategies for Early Diagnosis and Treatment of Sternoclavicular Joint Infection: Enhancing Outcomes and Reducing Mortality

Muhammad Umair\*, Muhammad Umer Farooq, Tarique Ahmed Maka

#### SUMMARY

Osteomyelitis is an infection involving bones. It may present in any part of the body but vertebral involvement is most common. After vertebral osteomyelitis, the most common site involved in hematogenous osteomyelitis is the flat bones of the axial skeletal system, such as the sternoclavicular and pelvic bones. Drug users are particularly at risk. It is most caused by *Staphylococcus aureus* and typically presents with localized pain, swelling, and erythema in the sternoclavicular region. We present a case of an 85-year-old male who is a known case of diabetes mellitus, ischemic heart disease, and hypertension who presented with sudden onset, high-grade fever, severe pain, difficulty in swallowing, and swelling over the Left sternoclavicular joint. Imaging studies revealed emphysematous osteomyelitis with abscess formation and subcutaneous emphysema. The patient underwent surgical drainage and was initiated on empirical intravenous antibiotics as blood for culture and sensitivity reports were awaited. The patient showed some improvement after the drainage and anti-biotics treatment, but after 3 days' the patient stopped responding to treatment. Follow-up imaging showed no resolution of the abscess, and clinical examination showed a freely mobile clavicle and increased pain. The patient died 10 days after the diagnosis of sternoclavicular joint emphysematous osteomyelitis and initiation of treatment due to extensive sepsis. Sternoclavicular joint osteomyelitis requires prompt diagnosis and a multidisciplinary approach involving infectious disease specialists and surgeons. Early surgical intervention combined with appropriate antibiotic therapy is crucial for successful management and prevention of complications. The rarity of this pathology with increased mortality prompted the case report

**Keywords:** *Clavicle, Osteomyelitis, Sternoclavicular Joint.*

**How to cite this:** Umair M, Farooq MU, Maka TA. A Multidisciplinary Approach to Sternoclavicular Joint Infection for Early Diagnosis and Treatment to Improve Disease Outcomes and Reduce Mortality. *Life and Science*. 2025; 6(1): 133-137. doi: <http://doi.org/10.37185/LnS.1.1.553>

This work is licensed under a Creative Commons Attribution-NonCommercial 4.0 International license. (<https://creativecommons.org/licenses/by-nc/4.0/>). Non-commercial uses of the work are permitted, provided the original work is properly cited.

#### Introduction

The sternoclavicular joint (SC joint) is a vital joint connecting the sternum (breastbone) and the clavicle (collarbone).<sup>1</sup> It plays a crucial role in the stability and movement of the shoulder girdle. While joint infections are relatively rare, they

can occur in the sternoclavicular joint, leading to a condition known as sternoclavicular joint infection or septic arthritis.<sup>2</sup> Chronic sternoclavicular joint osteomyelitis has been reported rarely and treated successfully with thoracotomy and multiple procedures.<sup>2</sup>

Sternoclavicular joint infections are generally caused by bacteria, most commonly *Staphylococcus aureus*, which can enter the joint through various means.<sup>2</sup> The infection may arise from nearby structures, such as the throat or teeth, or it can spread from distant sites through the bloodstream, as seen in systemic infections.

Department of Medicine  
Combined Military Hospital (CMH) Kharian, Pakistan  
Correspondence:  
Dr. Muhammad Umair  
Department of Medicine  
Combined Military Hospital (CMH) Kharian, Pakistan  
E-mail: [doctor.umair1997@gmail.com](mailto:doctor.umair1997@gmail.com)  
Received: Dec 12, 2023; Revised: Aug 16, 2024  
Accepted: Aug 20, 2024

It is also reported after head and neck surgeries and must be differentiated by prompt biopsies from malignancy.<sup>3</sup>

Common risk factors for sternoclavicular joint infection include immunosuppression (e.g., diabetes, HIV/AIDS), intravenous drug use, recent surgery or trauma, and the presence of indwelling devices like central venous catheters or pacemakers. It rarely occurs spontaneously in otherwise healthy individuals.<sup>4</sup>

The condition typically presents with pain, swelling, warmth, and redness in the region of the sternoclavicular joint. Cases of emphysematous osteomyelitis of pelvic bones are documented and have been published previously.<sup>4</sup> Patients may experience limited range of motion, discomfort during movement, and localized tenderness. In severe cases, systemic symptoms like fever, chills, and malaise may be present.

Diagnosis of sternoclavicular joint infection involves a thorough clinical examination, medical history review, and imaging studies such as X-rays, ultrasound, or magnetic resonance imaging (MRI).<sup>5</sup> Laboratory tests, including blood cultures and joint fluid analysis, are crucial for identifying the causative organism and guiding appropriate treatment.

Prompt treatment is essential to prevent complications and the spread of infection. Management typically involves a combination of medical and surgical interventions.<sup>6</sup> Antibiotics are administered to control the infection, and the choice of antibiotics depends on the suspected or identified pathogens.<sup>7</sup> In some cases, surgical intervention may be necessary to drain abscesses or remove infected tissue. Joint debridement or even joint fusion procedures may be required in severe infections.<sup>8</sup>

Overall, sternoclavicular joint infection is a rare but potentially serious condition that requires early diagnosis and intervention. With timely and appropriate treatment, the prognosis is generally favorable, although recovery may be a lengthy process requiring long-term antibiotic therapy and rehabilitation to restore joint function.<sup>9-12</sup>

### Case Report

An eighty-five-year-old, of average height and built male, presented to the medical OPD with the chief complaints of High-grade fever, difficulty in swallowing, and left-sided neck swelling.

On taking a detailed history, the patient was a known case of DM, IHD, and HTN. He was in his usual state of health until 10 days back, when he noticed swelling on the left side of his neck. The swelling increased rapidly in 06 days, and the patient developed a fever. Fever was sudden in onset, high grade, intermittent and documented not associated with rigors and chills. The swelling was tender and associated with difficulty in swallowing and speaking.

Before the onset of swelling, the patient complained of joint pain and morning stiffness in the knee, wrist, and shoulder joints. The patient took NSAIDs for pain but did not evaluate the symptoms and did not seek a medical consultation for joint pain.

On reporting, the patient underwent various examination modalities. The swelling was warm, firm, tender, and erythematous on physical examination. The swelling was non-transilluminating. On palpation of the sternoclavicular joint, the clavicle was freely mobile at its 2/3<sup>rd</sup> and tender. The patient was painful with direct palpation of the joint, passive and active range of motion of the ipsilateral shoulder joint, and surrounding neck as well. The gas bubbles were also palpable in the neck, suggestive of surgical emphysema. On examination of the chest, the patient had decreased entry of air on the left side with hyper-resonant percussion suggestive of pneumothorax.

The patient was advised USG Neck, CT Neck and chest, CT Brain, USG Thyroid, X-ray chest, and other laboratory tests such as Blood CP, CRP, ESR, Blood for C/S, Urine for C/S, LFTS, RFTs, Cardiac Enzyme, VBGs, Thyroid Profile, Serum electrolytes, RA factor, and anti-CCP antibodies. As shown in figure. 1, the erosion of left sternoclavicular joint is shown along with the emphysema of surrounding tissue.

As shown in figure. 2, the more extensive view

has been shown of neck and chest, it demonstrates the extensive infection of sternoclavicular joint and its extension to surrounding tissue of neck and chest along with extension to 1<sup>st</sup> rib.

Other than these investigations, RA factor and anti-CCP antibodies were also positive, but ANA was negative, which denotes that Rheumatoid Arthritis was the predisposing cause of Sternoclavicular joint osteomyelitis. In this case, a multi-disciplinary approach was required. ENT specialist, General Surgeon, Medical specialist, and highly efficient nursing care took good care of the case. After the report of the CT-Neck and

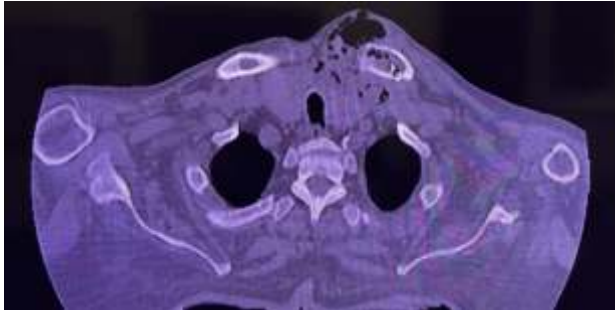


Fig.1: CT neck and chest

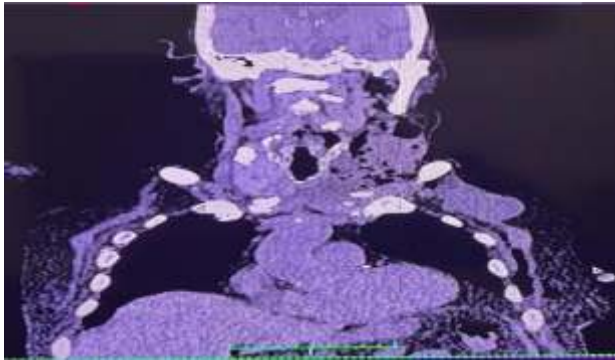


Fig.2: CT Neck and chest

were carried out, and the sample was sent for C/S. The empirical treatment was initiated. Broad-spectrum anti-biotics (Meropenem) were given along with Metronidazole as the results of Pus for C/S after drainage were awaited. The patient was in severe pain, so IV Tramadol was also given along with antibiotics. For the oral thrush, Nilstat oral drops were given. Along with all the treatment plans, high nursing care is ensured.

As the treatment was started, it was expected that the patient would recover soon. However, the condition of the patient kept on

deteriorating. All necessary steps were taken, but due to extensive sepsis, it was difficult for the patient to recover as osteomyelitis takes much more time for resolution. Seven days after the initiation of treatment, the Patient expired on 24<sup>th</sup> of June 2023 due to widespread sepsis.

### Discussion

Emphysematous sternoclavicular joint osteomyelitis is one of the rare types of osteomyelitis, which represents less than 1% of all bone and joint infections. It is traditionally followed by other systemic illnesses such as untreated rheumatoid arthritis, septic arthritis, IV drug abuse, clavicle trauma, infection of surrounding tissues, or direct trauma to the joint.<sup>1</sup> It is also difficult to diagnose due to its unusual presentation, and radiological interventions are needed.

We are presenting this case because it is essential to publish this kind of rare case as it will help other clinicians to diagnose and treat such cases in the future. In this case, the patient had swelling over the sternoclavicular joint and the symptoms of sepsis. The patient underwent various investigations and was diagnosed with sternoclavicular joint osteomyelitis. After multiple investigations, it was ruled out that Rheumatoid Arthritis was the underlying cause in this case.

In a study conducted by Ali M Al Ahmari, and Ibrahim M Alanis, the patient was 66 years old male who had been diagnosed with hypertension, IHD, and DM and had a history of PCI 4 months before presentation. In the study, a patient presented with shoulder pain and a restricted range of motion, and after 04 days, he developed a grade fever with chills. The examination showed some redness and fullness around the right SCJ, which was warm and tender upon palpation. Ultrasound revealed the right subpectoral muscle fluid collection inferior to the SCJ. The detailed assessment of the chest included MRI with contrast. It showed a chest wall abscess measuring 11 cm × 4 cm surrounding the SCJ extending posteriorly. The abscess was located at the junction of the right subclavian and internal jugular veins and

displaced the trachea to the left side. Osteomyelitis of the medial end of the clavicle was also detected. A provisional diagnosis of SCJ septic arthritis was hence confirmed radiographically. In our patient, CT head and neck showed Extensive soft tissue thickening and bone erosions with multiple air locules extending along the intermuscular planes, involving the left sternoclavicular joint and 1\* rib articulation. The lesion extends posteriorly displacing the thyroid gland, particularly the left lobe, and extending cranially along the left sternocleidomastoid muscle. which is blurred out by a tip lesion. There is a mass effect on the oropharynx, larynx, and trachea with contralateral deviation. The left clavicular head is eroded with air in medial 3\* of the marrow of the left clavicle, suggestive of osteomyelitis. The left medial end of the clavicle is subluxated from its articular surface.

In a study conducted by Ali M Al Ahmari and Ibrahim M Alanis, a protective osteotomy was performed to the medial 2 cm of the right clavicle, and debridement was carried out to the surrounding tissues and along the downward side of the surgical wound to drain the the pus pocket. A multidisciplinary approach was taken, and antibiotics were started according to the C/S reports, and the patient improved on the 5<sup>th</sup> day. In our study, the incision and drainage over the joint was carried out and sample send for C/S. The empirical treatment was initiated. Broad-spectrum anti-biotics (Meropenem) were given along with Metronidazole as the results of Pus for C/S after drainage were awaited. The patient was in severe pain, so IV Tramadol was also given along with antibiotics. For the Oral thrush, Nilstat oral drops were given. However, due to several factors, old age and extensive infection along with delayed presentation, lead to poor prognosis in our case.

This type of osteomyelitis requires a multidisciplinary approach as a medical specialist, General surgeon, orthopedic surgeon, and radiologist. Plastic surgery is also necessary after the stabilizing the patient for flap coverage if required.<sup>2</sup> With early diagnosis and treatment,

the prognosis is generally reasonable. But if a patient presents late and there is a delay in treatment, extensive sepsis develops, and the patient may develop extra-pleural or intra-thoracic abscesses, it would be difficult to eradicate the infection.<sup>6</sup> In such complicated cases, the mortality rate is usually high. So, it is very important in such cases to take a complete history to rule out any predisposing cause and make a provisional diagnosis to take the necessary steps for a good prognosis.

This study case will help in exploring the other causes of sternoclavicular joint infection and treatment options in management of disease as previously there is no adequate data available for sternoclavicular joint infection management. The study will help in future research and literature reviews for establishing the guidelines for management plan.

Certain limitations exist in our case presentation since this is a very rare occurrence, and there is no precise optimal management method regarding sternoclavicular joint infection reported in the literature. So, in this case, the investigations and treatment are potential points for discussion as they will affect the disease outcomes in the future. We believe this study provides a novel experience treating a group of diseases involving sternoclavicular joint infection.

Based on this study, we would suggest treating the cases of sternoclavicular joint osteomyelitis with early incision and debridement followed by the intensive course of intravenous antibiotics according to the culture and sensitivity report and before the C/S, with the empirical antibiotics according to the suspicion of causative agents followed by wound care for 2 to 4 weeks. Along with all these measures, controlling diabetes is a keystone in diabetic patients. The most severe cases will need surgical resection of infected bone followed by reconstructive surgery as needed.

### **Conclusion**

In this case, the physicians were able to diagnosed the condition as Emphysematous Sternoclavicular joint osteomyelitis based on

findings of CT Neck and chest and physical appearance of the swelling. The associated mortality and the optimal treatment options are not clear at present but an early multidisciplinary team approach may offer better prognosis.

**Acknowledgment:** None

**Conflict of Interest:** The authors declare no conflict of interest

**Grand Support and Financial Disclosure:** None

**REFERENCES**

1. Dajer-Fadel WL, Ibarra-Pérez C, Borrego-Borrego R, Navarro-Reynoso FP, Argüero-Sánchez R. Descending necrotizing mediastinitis and sternoclavicular joint osteomyelitis. *Asian Cardiovascular and Thoracic Annals*. 2013; 21: 618-20. doi:10.1177/0218492312463570
2. Gerscovich EO, Greenspan A. Osteomyelitis of the clavicle: clinical, radiologic, and bacteriologic findings in ten patients. *Skeletal radiology*. 1994; 23: 205-10. doi: 10.1007/BF00197463.
3. Tickell KD, Banim R, Kustos I. Salmonella sternoclavicular osteomyelitis in a patient with Crohn's disease. *Case Reports*. 2013; 2013: bcr2012007809. doi: 10.1136/bcr-2012-007809
4. Luey C, Tooley D, Briggs S. Emphysematous osteomyelitis: a case report and review of the literature. *International Journal of Infectious Diseases*. 2012; 16: e216-20. doi:10.1016/j.ijid.2011.11.007
5. Gordon RJ, Lowy FD. Bacterial infections in drug users. *New England Journal of Medicine*. 2005; 353: 1945-54. doi: 10.1056/NEJMra042823
6. Higginbotham TO, Kuhn JE. Atraumatic disorders of the sternoclavicular joint. *Journal of the American Academy of Orthopaedic Surgeons*. 2005; 13: 138-45. doi:10.5435/00124635-200503000-00007
7. Lindsey RW, Leach JA. Sternoclavicular osteomyelitis and pyoarthrosis as a complication of subclavian vein catheterization: a case report and review of the literature. *Orthopedics*. 1984; 7: 1017-22. doi:10.3928/0147-7447-19840601-18
8. Logan C, Shahien A, Altintas B, Millett PJ. Rehabilitation following sternoclavicular joint reconstruction for persistent instability. *International Journal of Sports Physical Therapy*. 2018; 13: 752-62.
9. Muesse JL, Blackmon SH, Ellsworth WA, Kim MP. Treatment of sternoclavicular joint osteomyelitis with debridement and delayed resection with muscle flap coverage improves outcomes. *Surgery Research and Practice*. 2014; 2014: 747315. doi:10.1155/2014/747315
10. Nusselt T, Klinger HM, Freche S, Schultz W, Baums MH. Surgical management of sternoclavicular septic arthritis. *Archives of orthopaedic and trauma surgery*. 2011; 131: 319-23. doi: 10.1007/s00402-010-1178-0
11. Ross JJ, Shamsuddin H. Sternoclavicular septic arthritis: review of 180 cases. *Medicine*. 2004; 83: 139-48. doi: 10.1097/01.md.0000126761.83417.29
12. Vu TT, Yammine NV, Al-Hakami H, Hier MP, Black MJ. Sternoclavicular joint osteomyelitis following head and neck surgery. *The Laryngoscope*. 2010; 120: 920-3. doi: 10.1002/lary.20849

**Authors Contribution**

**MU:** Study designing, data collection, data analysis, results and interpretation

**MUF:** Idea conception, study designing, manuscript writing and proofreading

**TAM:** Idea conception, data analysis, results and interpretation, manuscript writing and proofreading

.....