

ORIGINAL ARTICLE

Protective Effects of *Withania Somnifera* Against Cisplatin-Induced Acute Kidney Injury in Rats: A Histomorphometric Analysis

Aaqiba Rasheed^{1*}, Nadia Younus², Nausheen Jamshed³, Lubna Faisal⁴, Naureen Waseem¹, Rana Muhammad Zeeshan¹, Muhammad Omar Shamim⁵

ABSTRACT

Objective: This research aims to analyze the toxic effects of cisplatin and its amelioration by the root extract of *Withania Somnifera* on acute kidney injury in rat models through histomorphometric parameters.

Study Design: Experimental study.

Place and Duration of Study: The study was conducted at the Department of Anatomy and Animal House, Baqai Medical University Karachi, Pakistan from November 2018 to February 2019.

Methods: 80 adult male Albino Wistar rats split evenly into four groups for study purposes. No intervention was administered to Group A (control group), and Group B (treatment group) was given intraperitoneal injections of Cisplatin at 1mg/kg daily for 7 days. Group C (protected group) received ethanolic extract of *Withania somnifera* roots in an oral dose of 500mg/kg for 15 days before cisplatin treatment and continued with it till 22nd day. Group D (positive control group) was exclusively given *Withania somnifera* root extract 500mg/kg orally for 22 days' duration. Group B was anesthetized & sacrificed on the 8th day of study, while groups A, C, and D at the 23rd day. Kidneys from all sacrificed animals were carefully dissected and harvested for subsequent histomorphological analysis. This included analysis of Proximal convoluted tubule (PCT) count & PCT cell count under a microscope. Data were analyzed using SPSS version 22. One-way ANOVA was performed to compare groups, followed by post-hoc Tukey's test to assess the group differences.

Results: The final kidney weight of rats in cisplatin-treated group B showed a significant increase ($P<0.05$) as compared to groups C & D. However, no statistically significant differences in kidney weight were observed among the other groups ($P>0.05$). Microscopic examination of Group B kidneys revealed significant ($P<0.05$) histopathological changes in renal parenchyma. There was a decrease in the mean Proximal convoluted tubule count and Proximal convoluted tubule cell count of Cisplatin treated group. In contrast, Group C displayed preserved renal architecture ($P>0.05$).

Conclusion: This study concluded that pretreatment with *Withania Somnifera* root extract attenuates cisplatin-induced acute kidney injury, mediated by its antioxidant and anti-inflammatory properties. Histomorphological analysis revealed significant improvements in proximal tubule (PCT) count & PCT Cell count per reticula. *Withania Somnifera* also reduced kidney weight, which was increased due to renal parenchymal edema associated with cisplatin-induced inflammation.

Keywords: Acute Kidney Injury, Cisplatin, Proximal Convoluted Tubule, *Withania Somnifera*.

How to cite this: Rasheed A, Younus N, Jamshed N, Faisal L, Waseem N, Zeeshan RM, Shamim MO. Protective Effects of *Withania Somnifera* Against Cisplatin-Induced Acute Kidney Injury in Rats: A Histomorphometric Analysis. *Life and Science*. 2025; 6(1): 36-43. doi: <http://doi.org/10.37185/LnS.1.1.661>

This work is licensed under a Creative Commons Attribution-NonCommercial 4.0 International license.

(<https://creativecommons.org/licenses/by-nc/4.0/>). Non-commercial uses of the work are permitted, provided the original work is properly cited.

¹Department of Anatomy/Physiology⁵

Islam Medical College, Sialkot, Pakistan

²Department of Anatomy

Jinnah Medical and Dental College, Karachi, Pakistan

³Department of Anatomy

Karachi Institute of Medical Sciences, Karachi, Pakistan

⁴Department of Anatomy

Liaquat National Hospital and Medical College Karachi, Pakistan

Introduction

Nephrotoxicity emerges as a prevalent issue related to the kidneys, characterized by impaired renal function due to direct or indirect exposure to various agents, such as medications, industrial elements, and environmental factors

*Correspondence:**Dr. Aaqiba Rasheed**Assistant Professor, Anatomy**Islam Medical College Sialkot, Pakistan**E-mail: draaqiba@gmail.com**Received: Mar 20, 2024; Revised: Sep 26, 2024**Accepted: Oct 14, 2024*

like heavy metals, fungal toxins, and chemicals.¹

The primary association of nephrotoxicity is with drug usage, where drug-induced Acute kidney injury (AKI) accounts for 19–26% of all hospitalized cases.² AKI, previously referred as acute renal failure, is a sudden loss of excretory renal function due to reduction in the glomerular filtration rate. Sepsis, ischemia and nephrotoxicity are primary contributors in its pathophysiology.³

Cisplatin, a platinum-based drug, is the first line of chemotherapy in treating around 50% of solid tumors. While Cisplatin is mainly famous for its nephrotoxic and neurotoxic effects, adverse impacts are also observed in tissues like liver and spleen and systems like cardiovascular and pulmonary systems.⁴ Cisplatin is believed to eliminate cancer cells by interacting with DNA and forming DNA adducts in malignant cells, inhibiting its repair processes, leading to programmed cell death and apoptosis. Like other anti-cancer agents, Cisplatin triggers oxidative stress by producing Reactive Oxygen Species (ROS), a significant factor in the pathophysiology of inflammation and drug-related toxicity.⁵

The primary cause of toxicity induced by Cisplatin lies in its inadequate specificity for targeting only cancer cells, resulting in the dispersion of this chemotherapeutic agent to various organs throughout the body.⁶ As a matter of fact, there is documentation indicating that AKI is triggered in 20–30% of patients who receive the prescribed therapeutic dosage of cisplatin.⁷ The primary mechanism underlying Cisplatin-induced AKI includes oxidative stress causing inflammation, and injury to the proximal tubules, and vasculature.⁸

In addition to dietary measures and natural products, numerous plants have been utilized globally as potential nephroprotective agents. *Withania Somnifera* (WS), *Ashwagandha*, also

known as winter cherry, is a naturally occurring antioxidant, widely recognized for its nephroprotective effects. WS not only plays a significant role in enhancing the immune system, but it also exhibits anti-inflammatory, antibacterial, anticancer, antiarthritic, antidiuretic, and neuroprotective effects.⁹ While various plant parts hold medicinal value, roots are particularly recognized for their nephroprotective properties. The roots contain key active ingredients, namely Withaferin A and Withanolides, which play a crucial role in the biological efficacy of this plant.¹⁰ Research shows that antioxidant properties of WS enable it to neutralize free radicals and reactive oxygen species (ROS), thereby potentially preventing various disorders associated with radical activity.¹¹ No notable side effects or alterations in biochemical parameters were reported with its use. Less frequent side effects are typically limited to mild and mostly temporary adverse events.¹² Keeping in view of the above, the current study was designed to evaluate the protective effect of *W. Somnifera* root extract against cisplatin-induced nephrotoxicity by analyzing the morphometric changes in the kidneys of animals treated with cisplatin through histopathology slides.

Methods

This experimental study was done at the Department of Anatomy and Animal House, Baqai Medical University Karachi, Pakistan, from November 2018 to February 2019. Approval for the research was obtained from the Ethical Review Committee of Baqai Medical University Karachi, Pakistan, held on dated: 7th August 2018 vide letter no: BMC-EC/2018-02. A total of sixty adult male Albino Wistar rats, aged 14–16 weeks and weighing 200–250gm, were taken from the Animal House. With the exclusion of female and diseased animals, the remaining subjects underwent a 7-day adaptation period in the animal house, adhering to standard laboratory conditions, before commencing the experiment. Cisplatin injections (Inj.Cisplasil 50mg/50ml) were obtained from a local pharmacy to induce nephrotoxicity. The WS dried roots were

procured from a local market in Karachi, and the Department of Pharmacognosy, Karachi University, conducted the botanical identification. For our experimental study, we prepared an ethanol extract of WS roots.¹³

Eighty male albino rats were randomly assigned to four groups, each consisting of 20 rats and designated as A, B, C, and D. The control group (Group A) underwent no interventions, received distilled water orally for 22 days through gastric gavage, accompanied by 0.5ml normal saline injection (intraperitoneally) for a 7-day period. Group B was subjected to intraperitoneal injections of Cisplatin (1mg/kg) for seven consecutive days.¹⁴ Group C, designated as the protected group, received ethanolic extract of WS roots in an oral dose of 500mg/kg for 15 days before cisplatin treatment and continued with it till the 22nd day.¹⁵ Whereas group D was exclusively given the WS root extract at a dose of 500mg/kg orally for duration of 22 days to assess the potential adverse effects of WS on rat kidneys. Group B was anesthetized and then sacrificed on the 8th day, while groups A, C, and D were sacrificed on the 23rd day of the study. Subsequently, both kidneys underwent dissection, followed by H&E (Hematoxylin and Eosin) staining and histological analysis.

Prior to histological processing, the absolute weight (g) of each kidney was determined using an analytical balance.

The cortical area of the stained kidney (longitudinal section) was examined for morphometric changes in PCT count and PCT cell count using a light microscope with a 10x and 40x magnification objective lens. Micrometry was performed manually, utilizing a stage micrometer and an ocular micrometer.

For each kidney section, five fields were randomly analyzed. The average PCT count and PCT cell count per field is calculated. For cell counting purposes, an ocular reticule was inserted in the left eyepiece of the microscope. It was 100 squares, i.e., 10x10 squares. Calibration was performed using a stage micrometer, demonstrating that 1 division of a stage micrometer coincided with 4 four squares of

reticule along both the x and y axis. One square size was equal to $4/10 \times 2.5$ micrometers or 0.0025 mm, and the length of 10 squares was 25micrometer. The area of the whole reticule was $25 \times 25 = 625$ micrometer square or 0.0000625mm^2 .

Statistical data analysis was conducted using SPSS version 22. A comparison between groups was analyzed by using a one-way analysis of variance (ANOVA), and subsequently, a post hoc Tukey test was applied to assess the group differences. Results were considered statistically significant at the 95% confidence level ($P < 0.05$).

Results

A gross examination of the kidneys revealed no apparent abnormalities in size, shape, color, or texture. The mean (\pm SD) kidney weight, PCT count, and PCT cell count of Groups A, B, C & D are shown in table-1. Mean comparison between groups showed cisplatin induced nephrotoxicity by significant ($P < 0.05$) increase in kidney weight of group B. This increase was likely due to renal parenchymal edema associated with cisplatin-induced inflammation. However, no significant ($P > 0.05$) change in kidney weight of other groups were detected. WS treatment significantly attenuated this increase in kidney weight. Cisplatin treatment revealed severe PCT tubular degenerative features in group B, including a significant reduction in the mean PCT count and PCT cell count. However, pretreatment with WS in group C effectively preserved the number of cells and tubules in the PCT, maintaining normal values. No significant ($P > 0.05$) change of PCT count and PCT cell count was recorded in protected group C, shown in table-2.

Figure.1 illustrates the histological examination of renal tissue through H&E staining. Renal tubules of group A & D, exhibited normal morphology with densely packed PCTs, having narrow lumen lined by simple cuboidal epithelium with rounded nuclei and eosinophilic cytoplasm. The brush borders of the PCTs give them a characteristic fuzzy appearance under the microscope. However, cisplatin treated

Table-1: Descriptive Statistics of Group A, B, C & D

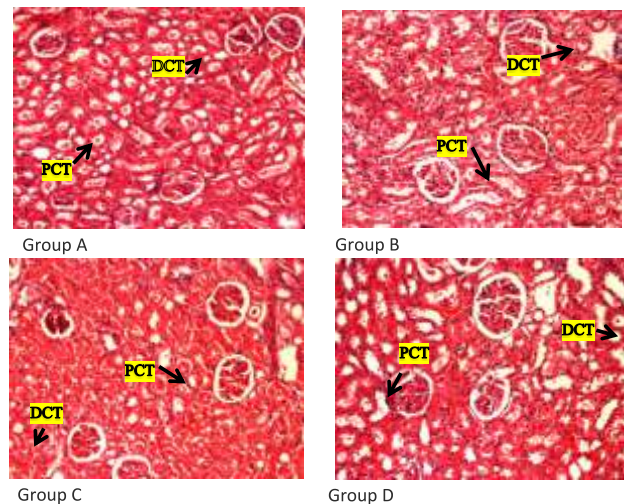
Parameters	Group A Mean± SD	Group B Mean ± SD	Group C Mean± SD	Group D Mean± SD
Kidney Wt. (gm)	0.592 ± 0.10	0.7383± 0.10	0.6019±0.08	0.5580±0.04
Proximal Convoluted Tubule Count	14.80±0.76	9.050±0.68	12.350± 0.58	14.750±0.71
Proximal Convoluted Tubule Cell Count per reticule	14.70±0.86	8.500± 0.82	12.350±0.74	14.700±0.80

Table-2: Statistical Analysis of Mean Count (Proximal Convoluted Tubule and Proximal Convoluted Tubule Cell) & Mean Kidney Weight of Rats between Different groups

Groups Comparison	Mean PCT Count		Mean PCT Cell Count		Mean Kidney Weight (gm)	
	Difference of Means	P-value	Difference of Means	P-value	Difference of Means	P-value
B & A	5.75	0.000*	6.2	0.000*	0.14	0.000*
B & C	3.3	0.000*	3.85	0.000*	0.13	0.002*
B & D	5.7	0.000*	6.2	0.000*	0.18	0.001*
C & A	2.45	0.000*	2.35	0.000*	0.00	0.738
C & D	2.4	0.000*	2.35	0.000*	0.04	0.044
A & D	0.05	0.996	0	1.000	0.03	0.177

Statistically significant (P-value ≤ 0.05)

group B exhibited extensive degenerative changes in H&E section. Architectural damage is particularly pronounced in the PCT. The PCT lumina showed marked dilation with excessive debris accumulation. PCT cells displayed shedding of brush borders and prominent necrotic features, including vacuolar degeneration. Interstitial areas of the renal parenchyma revealed infiltrating inflammatory cells and areas of inter-tubular hemorrhage. While the protected group C displayed preserved renal architecture and improved tubular necrosis compared to the cisplatin-treated group. Inflammatory cells infiltrate and inter-tubular hemorrhage were markedly attenuated. The PCT and PCT cells exhibited minimal degenerative changes. Group A (Control) illustrating normal renal architecture and renal tubules with densely packed PCTs and

**Fig.1: Photomicrograph of rat renal tissue (H&E x 100)**

fewer DCTs. Group B (cisplatin treated) exhibiting extensive degenerative changes in PCT having marked dilation & debris accumulation. Group C (Protected) showing preservation of renal parenchyma with

improvement in tubular necrotic changes. Group D shows unaltered renal parenchymal architecture.

Discussion

This experimental study was designed to analyze the potential kidney damage caused by cisplatin alone and the potential protective effects of *Withania Somnifera* root extract against cisplatin-mediated AKI in rats through histomorphometric changes.

It is widely recognized that drugs are mainly metabolized in the Liver and excreted through the kidney. Renal clearance of drugs occurs either by glomerular filtration or tubular secretion, exposing tubules and interstitium to toxic metabolites.² PCT is the one which is most affected as it receives not only glomerular filtrate from the renal corpuscle but itself also secretes metabolites, reuptakes them through their epithelial cells, and maintains apical efflux through the basolateral surface of epithelial cells from the peritubular circulation into the lumen.¹⁶ AKI affecting PCT is dose-dependent. The proximal tubular injury and acute tubular necrosis (ATN) occur when: drugs or their metabolites come in direct contact with apical surfaces of tubular epithelial cells; drugs are transported through the apical surface of tubular epithelial cells; or drugs undergo basolateral secretion into the tubular lumen. The basolateral membrane of renal epithelial cells houses human organic anion transporters (hOATs) and human organic cation transporters (hOCTs). These facilitate the excretion of negatively and positively charged molecules, respectively, into the tubular lumen via efflux transporters. Drugs and metabolites injure tubular epithelial cells by accumulating in the cytoplasm and generating ROS, leading to necrosis, exfoliation, or water and solute transport dysfunction.¹⁷ Drug accumulation damages mitochondria, reducing ATP production and triggering apoptosis via DNA polymerase γ inhibition or caspase activation.²

Cisplatin is among the most effective platinum-based antineoplastic agents, used for a large range of cancers. Cisplatin undergoes

glomerular filtration and is reabsorbed /secreted in proximal tubules. Its main elimination pathway is the secretion at the basolateral proximal tubular cell's hOCT and apical membrane efflux transporter (hMATE1). These transporters facilitate cisplatin uptake by renal tubular cells.¹⁸ The pathophysiology of Cisplatin-induced AKI involves renal tubular apoptosis due to elevated levels of p53 pathway metabolites. Cisplatin also triggers inflammation by up-regulating inflammatory mediators like Cyclooxygenase 2 (COX-2), Inducible nitric oxide synthase (iNOS), intercellular adhesion molecule-1 (ICAM-1), Monocyte chemoattractant protein-1 (MCP-1), IL-6, and TNF- α through the NF-KB (Nuclear factor kappa-light-chain-enhancer of activated B cells) pathway while simultaneously suppressing antioxidant defenses like Superoxide dismutase (SOD) and Glutathione S-transferases (GST) through Nrf2 (Nuclear factor erythroid 2-related factor 2) pathway inhibition. In this experiment, seven days of cisplatin administration induced nephrotoxic changes in rats, evident by increased kidney weight and histological evidence of degeneration, particularly in the proximal convoluted tubules (PCT). Dilated PCT lumens contained cellular debris and casts. PCT epithelium displayed brush border loss and necrosis. Histomorphometry showed a decrease in PCT and PCT cell count. Areas of inter-tubular hemorrhage and infiltration of inflammatory cells in the interstitium are also evident. These findings agree with the cisplatin experiment of Sohail N. et al., which demonstrated that cisplatin-induced AKI is due to the reduction in anti-oxidative metabolites like glutathione, increase in oxidative stress markers of lipid peroxidation, and inflammatory catalase levels.¹⁹ McSweeney KR. et al. explained the pathophysiology of cisplatin-induced AKI in PCT, highlighting its association with altered cellular uptake and efflux, apoptosis, oxidative stress, endoplasmic reticulum stress, and inflammation in the interstitium and peri-vascular injury. Within the PCT epithelial cell, cisplatin undergoes hydroxylation, generating its active

metabolite, which is conjugated with glutathione, the main cellular antioxidant, by the cytoplasmic enzyme GST. Cisplatin metabolites deplete glutathione, triggering ROS-mediated apoptosis in PCT epithelial cells via MAPK, p53, and p21 protein activation.¹⁸ ROS accumulation occurs not only in the cytoplasm but also in mitochondria, endoplasmic reticulum, and microsomes. Therefore, it can be stated that oxidative stress, marked by ROS accumulation and DNA damage, is the foundation of cisplatin-induced AKI.^{20,18} Cisplatin exacerbates inflammation by activating poly ADP-ribose polymerase 1 (PARP-1), leading to increased production of pro-inflammatory cytokines like IL-1, IL-6, and TNF- α , particularly TNF- α , which further intensifies tubular inflammation.²¹ Since ROS production is the primary mechanism of platinum-based drug toxicity, research has investigated various antioxidants, including vitamins C and E, selenium, alpha-lipoic acid, and DMTU, for their potential to mitigate AKI.¹⁸ Similarly, this study investigated the use of *Withania somnifera*, another potential protective agent, against cisplatin-induced AKI.

Withania Somnifera has been a widely used herb for more than 3000 years in traditional Ayurvedic and Unani medicine. Its main pharmacological actions are attributed to its primary active ingredient, which is withanolide alkaloids, and secondary metabolites, which include flavonoids, steroids, phenolics, alkaloids, glycosides, and saponins.²² *Withania somnifera* exhibits potential in DNA repair, cellular restoration, and preventing healthy cell death, suggesting a complementary therapy for disease management.²³ In the present study, Group C exhibited preserved renal architecture. Cisplatin-induced AKI and associated tubular necrosis improved significantly. Inflammation and inter-tubular bleeding were markedly reduced. The PCT and PCT cell count per reticule were improved. These protective effects can be attributed to WS's protective effects, as documented by Namdev et al. They demonstrated a significant reduction in oxidative indicators

like Hydrogen peroxide, Nitric oxide, Lipid peroxidase, and Catalase in renal tissue. Moreover, there was an increase in renal tissues' antioxidative biomarkers like Glutathione reductase, GST, and SOD, which prevents the AKI caused by ROS.²⁴ Bhat JA. et al. explained that the ameliorating effects of WS lie in its property to enhance DNA repair processes. By improving DNA damage caused by cisplatin, it halts cellular apoptosis.²⁵ Hematological improvements by WS, as seen through renal function estimations against cisplatin, have previously been reported by Aswar AP. et al. Rasheed A. et al. and Akhtar F. et al. They all ascribed the renal improvement to the antioxidant effects of *Withania Somnifera*.^{25,26} Aswar AP. et al. not only demonstrated hematobiochemical markers' improvement due to WS but also renal weight reductions as well histological improvements of AKI, including focal tubular necrosis, intratubular hyaline cast, peritubular mononuclear infiltration, venous congestion and intra and inter-tubular hemorrhages.²⁷ WS not only protects from AKI but also protects against disease progression in Chronic Kidney Disease mouse models by its active compound Withaferin A, which halts the progression of disease with the restraint of ER stress-related apoptosis, inflammation, and fibrosis in the kidneys.²⁸

Our study conclusively demonstrates the efficacy of *Withania Somnifera* roots in protecting against drug-induced nephrotoxicity. Future research utilizing HPLC analysis would provide valuable insights into the specific bioactive compounds within the *Withania Somnifera* root extract responsible for its nephroprotective properties.

Conclusion

This experimental study in a rat model demonstrated that *Withania Somnifera* root extract significantly ameliorated cisplatin-induced acute kidney injury (AKI), as evidenced by the improvement of histomorphometric parameters. This nephroprotective effect is attributed to the extract's antioxidant and anti-inflammatory properties. These findings suggest

that *Withania Somnifera* may have the potential as an adjunct therapy to mitigate the adverse renal effects of cisplatin and allow for its continued use in patients with reduced risk of nephrotoxicity.

Acknowledgment: None

Conflict of Interest: The authors declare no conflict of interest

Grant Support and Financial Disclosure: Baqai Medical University, Karachi

REFERENCES

- Huo X, Liu K. Renal organic anion transporters in drug–drug interactions and diseases: European Journal of Pharmaceutical Sciences 2018; 112: 8-19. doi: 10.1016/j.ejps.2017.11.001
- Kwiatkowska E, Domański L, Dziedzicko V, Kajdy A, Stefańska K, Kwiatkowski S. The mechanism of drug nephrotoxicity and the methods for preventing kidney damage. International Journal of Molecular Sciences. 2021; 22: 6109. doi: 10.3390/ijms22116109
- Kellum JA, Romagnani P, Ashuntantang G, Ronco C, Zarbock A, Anders HJ. Acute kidney injury. Nature reviews Disease primers. 2021; 7: 52. doi: 10.1038/s41572-021-00284-z
- Rix A, Drude NI, Mrugalla A, Baskaya F, Pak KY, Gray BA, et al. Assessment of Chemotherapy-Induced Organ Damage with Ga-68 Labeled Duramycin. Molecular Imaging and Biology. 2020; 22: 623-33. doi: 10.1007/s11307-019-01417-3
- Ibrahim MA, Khalifa AM, Mohamed AA, Galhom RA, Korayem HE, Abd El-Fadeal NM, et al. Bone-marrow-derived mesenchymal stem cells, their conditioned media, and olive leaf extract protect against cisplatin-induced toxicity by alleviating oxidative stress, inflammation, and apoptosis in rats. Toxics. 2022; 10: 526. doi: 10.3390/toxics10090526
- Byun EB, Song HY, Kim WS, Han JM, Seo HS, Park SH, et al. Protective effect of polysaccharides extracted from *Cudrania tricuspidata* fruit against cisplatin-induced cytotoxicity in macrophages and a mouse model. International Journal of Molecular Sciences. 2021; 22: 7512. doi: 10.3390/ijms22147512
- Hazman Ö, Bozkurt MF, Fidan AF, Uysal FE, Çelik S. The effect of boric acid and borax on oxidative stress, inflammation, ER stress and apoptosis in cisplatin toxication and nephrotoxicity developing as a result of toxication. Inflammation. 2018; 41: 1032-48. doi: 10.1007/s10753-018-0756-0
- McSweeney KR, Gadanec LK, Qaradakhi T, Ali BA, Zulli A, Apostolopoulos V. Mechanisms of cisplatin-induced acute kidney injury: pathological mechanisms, pharmacological interventions, and genetic mitigations. Cancers. 2021; 13: 1572. doi:10.3390/cancers13071572
- Gupta S, Bansal RN, Sodhi SP, Brar GK, Molhotra M. Ashwagandha (*Withania somnifera*)—a herb with versatile medicinal properties empowering human physical and mental health. Journal of Pre-Clinical and Clinical Research. 2021; 15: 129-33. doi: 10.26444/jpccr/141582
- Paul S, Chakraborty S, Anand U, Dey S, Nandy S, Ghorai M, et al. *Withania somnifera* (L.) Dunal (Ashwagandha): A comprehensive review on ethnopharmacology, pharmacotherapeutics, biomedical and toxicological aspects. Biomedicine & Pharmacotherapy. 2021; 143: 112175. doi: 10.1016/j.biopha.2021.112175
- Tyagi N, Tyagi M, Tyagi J. Antimicrobial and antioxidant activities of *Withania somnifera* (Ashwagandha). International Research Journal of Modernization in Engineering Technology and Sciences. 2021; 3: 3570-83.
- Tandon N, Yadav SS. Safety and clinical effectiveness of *Withania Somnifera* (Linn.) Dunal root in human ailments. Journal of ethno pharmacology. 2020; 255: 112768. doi: 10.1016/j.jep.2020.112768
- Dhanani T, Shah S, Gajbhiye NA, Kumar S. Effect of extraction methods on yield, phytochemical constituents and antioxidant activity of *Withania somnifera*. Arabian journal of chemistry. 2017; 10: S1193-9. doi: 10.1016/j.arabjc.2013.02.015
- Singh N, Sharma AK, Magotra R, Ahmed M. Histomorphological effects of cisplatin on kidney of male wistar albino rats. Journal of Evolution of Medical and Dental Sciences. 2015; 4: 8526-31. doi: 10.14260/jemds/2015/1235
- Shimmi SC, Jahan N, Baqi N, Rahman Z. Histological evidence of nephroprotective effect of Ashwagandha (*Withania somnifera*) root extract against gentamicin induced nephrotoxicity in rats. Journal of Enam Medical College. 2014; 4: 26-30. doi: 10.3329/jemc.v4i1.18065
- Perazella MA, Rosner MH. Drug-induced acute kidney injury. Clinical Journal of the American Society of Nephrology. 2022; 17: 1220-33. doi: 10.2215/CJN.11290821
- Aldossary SA. Review on pharmacology of cisplatin: clinical use, toxicity and mechanism of resistance of cisplatin. Biomedical and Pharmacology Journal. 2019; 12: 7-15. doi: 10.13005/bpj/1608
- McSweeney KR, Gadanec LK, Qaradakhi T, Ali BA, Zulli A, Apostolopoulos V. Mechanisms of cisplatin-

- induced acute kidney injury: pathological mechanisms, pharmacological interventions, and genetic mitigations. *Cancers*. 2021; 13: 1572. doi: 10.3390/cancers13071572
19. Sohail N, Hira K, Kori JA, Farhat H, Urooj F, Khan W, et al. Nephroprotective effect of ethanol extract and fractions of a sea lettuce, *Ulva fasciata* against cisplatin-induced kidney injury in rats. *Environmental Science and Pollution Research*. 2021; 28: 9448-61. doi:10.1007/s11356-020-11321-x
 20. Qi X, Wang J, Fei F, Gao X, Wu X, Shi D, et al. Myricetin-Loaded Nanomicelles Protect against Cisplatin-Induced Acute Kidney Injury by Inhibiting the DNA Damage-cGAS–STING Signaling Pathway. *Molecular Pharmaceutics*. 2022; 20: 136-46. doi: 10.1021/acs.molpharmaceut.2c00520
 21. Güntürk I, Yazici C, Köse SK, Dağlı F, Yücel B, Yay AH. The effect of N-acetylcysteine on inflammation and oxidative stress in cisplatin-induced nephrotoxicity: a rat model. *Turkish Journal of Medical Sciences*. 2019; 49: 1789-99. doi: 10.3906/sag-1903-225
 22. Saleem S, Muhammad G, Hussain MA, Altaf M, Bukhari SN. *Withania somnifera* L: Insights into the phytochemical profile, therapeutic potential, clinical trials, and future prospective. *Iranian Journal of Basic Medical Sciences*. 2020; 23: 1501-26. doi: 10.22038/IJBMS.2020.44254.10378
 23. Bhat JA, Akther T, Najar RA, Rasool F, Hamid A. *Withania somnifera* (L.) Dunal (Ashwagandha); current understanding and future prospect as a potential drug candidate. *Frontiers in Pharmacology*. 2022; 13: 1029123. doi:10.3389/fphar.2022.1029123
 24. Namdev N, Rai G, Mahobiya P. The pharmacological role of Ashwagandha in cypermethrin-induced spleen toxicity in mice. *Research Journal of Pharmacy and Technology*. 2023; 16: 3264-8. doi: 10.52711/0974-360X.2023.00537
 25. Vasavan SS, Jagadesan V, Sivanesan S, Rajagopalan V. Protective effect of *Withania somnifera* on nandrolone decanoate-induced biochemical alterations and hepatorenal toxicity in wistar rats. *Pharmacognosy Magazine*. 2020;16: 218-223. doi: 10.4103/pm.pm_349_19
 26. Akhtar F, Azhar M, Aslam M, Javed K. Nephroprotective effect of asgand powder (*Withania somnifera* dunal) on cisplatin induced renal injury in rats. *Journal of Drug Delivery and Therapeutics*. 2020; 10: 22-5. doi: 10.22270/jddt.v10i6-s.4580
 27. Aswar AP, Hajare SW, Ingole RS, Ingawale MV, Kuralkar PS, Waghmare SP. Nephroprotective Effects of Polyherbal Formulation on Gentamicin-induced Toxicity in Wistar Rats. *Indian Journal of Veterinary Sciences & Biotechnology*. 2022; 18: 10-4. doi: 10.48165/ijvsbt.18.4.03
 28. Chen CM, Chung YP, Liu CH, Huang KT, Guan SS, Chiang CK, et al. Withaferin A protects against endoplasmic reticulum stress-associated apoptosis, inflammation, and fibrosis in the kidney of a mouse model of unilateral ureteral obstruction. *Phytomedicine*. 2020; 79: 153352. doi: 10.1016/j.phymed.2020.153352

Authors Contribution

AQ: Idea conception, study designing, data collection, data analysis, results and interpretation, manuscript writing and proofreading

NY: Manuscript writing and proofreading

NJ: Data collection

LF: Manuscript writing and proofreading

NW: Manuscript writing and proofreading

RMZ: Data analysis, results and interpretation

MOS: Data analysis, results and interpretation