

CASE REPORT

Rett Syndrome without MECP2 Mutation in a Pakistani Girl

Rubina Dad¹, Humaira Aziz Sawal², Arsalan Ahmad³, Muhammad Ikram Ullah⁴, Muhammad Jawad Hassan⁵

ABSTRACT

Rett syndrome is a rare inherited neurodegenerative disease which mostly affects females but has a lethal impact on males. Rett syndrome is mostly caused by mutations of Methyl CpG binding protein-2 (*MECP2*) gene located on chromosome Xq28.

A 7-year girl from a consanguineous Pakistani family presented with history of abnormal social behavior, tonic colonic seizures, limb'sataxia, intellectual disability, growth retardation and speech abnormalities. Physical and neurological examinations established likely clinical features of Rett syndrome with abnormal electroencephalogram (EEG). Genetic testing of *MECP2* gene did not identify any functional nucleotide variation indicating the involvement of another gene mutation in this patient.

A consanguineous case of Rett syndrome did not carry the mutation of *MECP2* gene. Due to heterogeneity of the phenotype, it is proposed that there might be involvement of another locus for this disease. In future, targeted next generation sequence can be helpful to identify the causative mutation in this patient.

Key Words: *MECP2, Pakistan, Rett Syndrome, Seizures.*

How to cite this: Dad R, Sawal HA, Ahmad A, Ullah MI. Rett Syndrome without MECP2 Mutation in a Pakistani Girl. *Life and Science*. 2020; 1(2): 83-85. doi: <http://doi.org/10.37185/LnS.1.1.77>

This is an Open Access article distributed under the terms of the Creative Commons Attribution License (<http://creativecommons.org/licenses/by/4.0>), which permits unrestricted use, distribution, and reproduction in any medium, provided the original work is properly cited.

Introduction

Rett syndrome (RTT; OMIM 312750) is a rare neurodevelopmental disorder with prevalence of 1 in 15,000 in females.¹ Clinical features include ataxia, loss of speech abilities, seizures onset, intellectual disability, severe developmental delay, cognitive impairments, breathing and swallowing difficulties, chewing and teeth grinding issues and sleep disorders.² Methyl-CpG-binding protein 2 (*MECP2*)

gene is responsible for typical RTT in 95% patients and with different RTT feature in 73.2% patients.³ Other genes like forkhead box protein G1 (*FOXG1*), *GRIN1* and *KIF1A* and cyclin-dependent kinase-like 5 (*CDKL5*) have been demonstrated in congenital RTT and as pathogenic genes of early seizures.^{4,5}

The most common causative gene for Rett syndrome is *MECP2* (NM_001110792) which is located at candidate region on chromosome Xq28; however, recently some other genes have been identified for this phenotype.⁴ A number of mutations in *MECP2* have been reported in different ethnic groups and populations.^{6,7} According to various reports, 70%-80% cases of Rett syndrome show mutations in *MECP2* gene while other cases are associated with other genes.⁸ Depending on the cell type and development phases in the brain, *MECP2* imparts variable effects in these processes. RTT is reflected to the failure of functions at different levels, like gene regulation and expression, synaptic function and neuronal circuitry, and during developmental stages.⁹

In the present study, we ascertained a consanguineous family with one affected girl who showed classical features of Rett syndrome and mutation screening of *MECP2* gene did not reveal

¹Department of Applied Biosciences
Atta-ur-Rahman School of Applied Biosciences (ASAB)
National University of Sciences & Technology (NUST), Islamabad

²Armed Forces Institute of Pathology
Combined Military Hospital, Rawalpindi

³Division of Neurology
Shifa International Hospital
Shifa Tameer e Millat University (STMU), Islamabad

⁴Department of Clinical Laboratory Sciences
Jouf University, Kingdom of Saudi Arabia

⁵NUMS Department of Biological Sciences
National University of Medical Sciences (NUMS), Rawalpindi

Correspondence:

Dr. Muhammad Jawad Hassan
Associate Professor, Biological Sciences
National University of Medical Sciences, Rawalpindi
E-mail: jawad.hassan@numspak.edu.pk

Funding Source: NIL; Conflict of Interest: NIL
Received: Oct 14, 2019; Revised: Feb 19, 2020

Accepted: Mar 02, 2020

any nucleotide variation. Thus establishing the basis of heterogeneity of this disorder.

Case Presentation

A 7-year old girl visited the hospital, with a history of hyperactive behavior, delayed milestones, generalized tonic clonic seizures, (onset at 6-month age). Her family history showed a consanguineous relationship between her parents (Fig 1). She was treated previously with medication and remained asymptomatic, followed by a period of relapse. She had remained stable for 2-3 years. Since past three to four years, she had become aggressive.

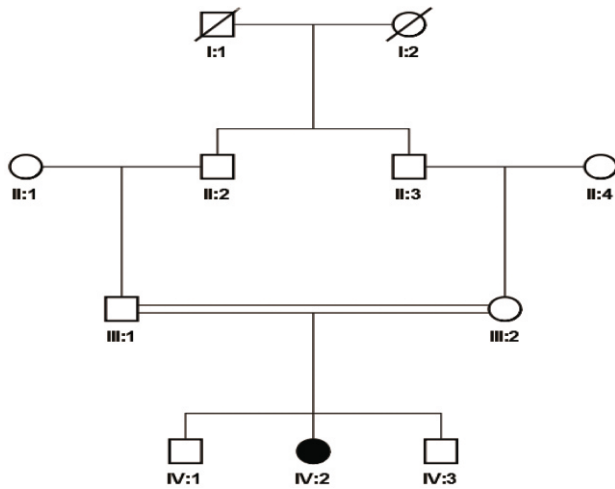


Fig 1: Pedigree representation of family. Filled circle shows affected female and clear squares and circles represent normal individuals. Horizontal line between two individuals demonstrates the relation while vertical lines describe the generations

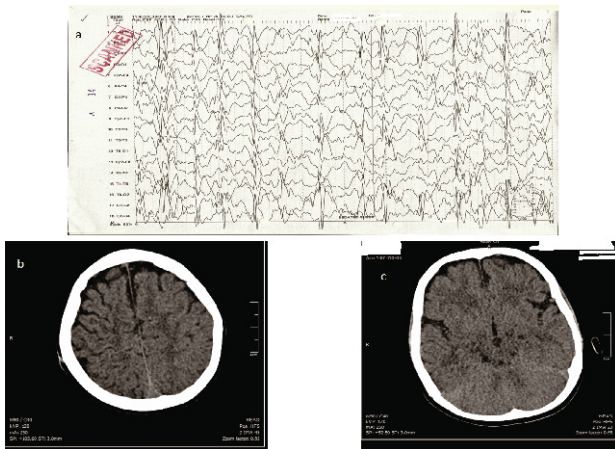


Fig 2: Electroencephalogram and CT scan of affected girl a: EEG shows generalized spike b and c: CT scan of brain showed bilateral atrophic changes

On recent clinical examination, she was mentally slow with partial loss of fluency of the language and speech. She also developed stereotypic hand movements bilaterally. She had disturbance in breathing when awake and showed impaired sleep pattern. She had growth retardation and with small hands and feet. She was having inappropriate screaming spells, with intense eye communication. Neurological examination revealed normal cranial nerve functions. Manual muscular testing showed weakness of limb and abnormal muscle tone. Her deep tendon reflexes were normal and symmetrically preserved. Her planter response was equivocal on right side and flexor on left side. Electroencephalogram (EEG) showed frequent generalized spikes and wave discharges with mild background slopping and CT scan of head with chest showed bi-frontal atrophy (Fig 2 a, b, c). Urine for mucopolysaccharidosis was negative and Benedict's test for urine glucose was negative. These tests were performed to rule out mucopolysaccharidosis, as there is symptoms overlap. She was given carbamazepine 100mg twice a day with calcium supplements. Genetic testing of *MECP2* gene did not identify any functional nucleotide variation associated with this phenotype.

Table 1: General clinical features of Rett syndrome and comparison with features diagnosed in the patient

Age of onset for Rett syndrome	6-18 months				
Present study	6 months				
Primary characteristics	Loss of Speech	Reduced Head Growth	Stereotypic Hand Movements	Motor Dysfunction	Autism-Like Features
Present study	Yes	Yes	Yes	Yes	Yes
Peripheral phenotypes	Spinal Deformity	Principally Scoliosis and Excessive Kyphosis	Scoliosis	Reduced Bone Mass	
Present study	N/A	N/A	N/A	Yes	
Major disease gene	<i>MECP2</i>				
Present study	No Mutation Found				
Skeletal anomalies	Early Osteoporosis	Osteopenia	Bone Fractures	And Hip Deformities	
Present study	N/A	N/A	Yes	Yes	

Discussion

Rett syndrome is a rare neurodevelopmental disease of childhood. It presents with diverse clinical features like abnormal social interactions, seizures, ataxia, microcephaly, speech and swallowing abnormalities, intellectual disability, delay in growth

and loss of motor movements at later stage of disease.¹⁰ Mutations may be present in *MECP2* or other related genes including *CDKL5*, *FOXP1*, *GRIN1* and *KIF1A*.^{5,11}

In the present case, we report a girl who showed hyperactive social behavior, fits and seizure, loss of speech abilities, limb weakness, intellectual disability and growth retardation. Her EEG showed abnormal wave discharge confirming epileptic fits and CT-scan showed atrophic changes. Supportive diagnosis of Rett syndrome included breathing difficulties, abnormal EEG and seizures, spasticity and ataxia, microcephaly, intellectual disability and delay in growth.¹²

Genetic testing in the present case did not find mutation in *MECP2* gene although most common mutations reported worldwide are in *MECP2*.³ Mutations in genes other than *MECP2*, including *CDKL5*, *FOXP1*, *GRIN1* and *KIF1A*, are also reported in families with Rett like features due to genetic heterogeneity of this disease.^{5,11}

In Pakistan, very few reports with Rett syndrome epilepsy have been described. Although, diverse features make differential diagnosis very complicated, molecular studies established mutations in *MECP2* and *FOXP1* in our country.¹³⁻¹⁵

Next generation sequencing is a remarkable tool for identification of causative genes in heterogeneous disorders like Rett syndrome.

Conclusion

This is the fourth case of Rett syndrome reported from Pakistan and this case is without *MECP2* gene mutations. In future, other known genes will be sequenced to identify the pathogenic variant through next generation sequencing in this girl.

Acknowledgments

We are thankful to the family for participating in this research.

REFERENCES

1. Ermel ÉL, Carneiro LC, Souza CF, Crippa AC, Sanseverino MT, Raskin S. Epileptic encephalopathy and atypical Rett syndrome with mutations in *CDKL5*: clinical and molecular characterization of two Brazilian patients. *Arquivos de neuro-psiquiatria*. São Paulo. 2013; 71: 414-5.
2. Olson HE, Tambunan D, LaCoursiere C, Goldenberg M,

- Pinsky R, Martin E, et al. Mutations in epilepsy and intellectual disability genes in patients with features of Rett syndrome. *American Journal of Medical Genetics Part A*. 2015; 167: 2017-25.
3. Percy AK, Neul JL, Glaze DG, Motil KJ, Skinner SA, Khwaja O, et al. Rett syndrome diagnostic criteria: lessons from the Natural History Study. *Ann Neurol*. 2010; 68: 951-5.
4. Tao J, Van Esch H, Hagedorn-Greiwe M, Hoffmann K, Moser B, Raynaud M, et al. Mutations in the X-linked cyclin-dependent kinase-like 5 (*CDKL5/STK9*) gene are associated with severe neurodevelopmental retardation. *Am J Hum Genet*. 2004; 75: 1149-54.
5. Wang J, Zhang Q, Chen Y, Yu S, Wu X, Bao X. Rett and Rett-like syndrome: Expanding the genetic spectrum to *KIF1A* and *GRIN1* gene. *Mol Genet Genomic Med*. 2019; 11: e968.
6. Amir RE, Van den Veyver IB, Wan M, Tran CQ, Francke U, Zoghbi HY. Rett syndrome is caused by mutations in X-linked *MECP2*, encoding methyl-CpG-binding protein 2. *Nature genetics*. 1999; 23: 185.
7. Nasiri J, Salehi M, Hosseinzadeh M, Zamani M, Fattahpour S, Aryani O, et al. Genetic Analysis of *MECP2* Gene in Iranian Patients with Rett Syndrome. *Iran J Child Neurol*. 2019; 13: 25-34.
8. Tarquinio DC, Hou W, Neul JL, Lane JB, Barnes KV, O'Leary HM, et al. Age of diagnosis in Rett syndrome: patterns of recognition among diagnosticians and risk factors for late diagnosis. *Pediatric neurology*. 2015; 52: 585-91.
9. Dolce A, Ben-Zeev B, Naidu S, Kossoff EH. Rett syndrome and epilepsy: an update for child neurologists. *Pediatric neurology*. 2013; 48: 337-45.
10. Cianfaglione R, Clarke A, Kerr M, Hastings RP, Oliver C, Felce D. A national survey of Rett syndrome: Age, clinical characteristics, current abilities, and health. *American Journal of Medical Genetics Part A*. 2015; 167: 1493-1500.
11. Williamson SL, Ellaway CJ, Peters GB, Pelka GJ, Tam PP, Christodoulou J. Deletion of protein tyrosine phosphatase, non-receptor type 4 (*PTPN4*) in twins with a Rett syndrome-like phenotype. *European Journal of Human Genetics*. 2015; 23: 1171.
12. Kaufmann WE, Johnston MV, Blue ME. *MECP2* expression and function during brain development: implications for Rett syndrome's pathogenesis and clinical evolution. *Brain and Development*. 2005; 27: S77-S87.
13. Hussain A, Khan MA, Qazi SA, Rehman GN. The Rett syndrome: the first case report from Pakistan. *Brain and Development*. 1991; 13: 442-4.
14. Sheikh TI, Harripaul R, Ayub M, Vincent JB. *MECP2* AT-Hook1 mutations in patients with intellectual disability and/or schizophrenia disrupt DNA binding and chromatin compaction in vitro. *Human Mutation*. 2018; 39: 717-28.
15. Khan AA, Kirmani S. Mild presentation of the congenital variant Rett syndrome in a Pakistani male: expanding the phenotype of the forkhead box protein G1 spectrum. *Clinical Dysmorphology*. 2019.