

## ORIGINAL ARTICLE

**Diagnostic Accuracy of MRI in Delineation of Ultrasonographically Indeterminate Female Adnexal Lesions keeping Histopathology as Gold Standard**Madiha<sup>1</sup>, Farkhanda Jabeen<sup>2</sup>, Nadia Gul<sup>3</sup>, Khalid Mehmood<sup>4</sup>, Salma Umbreen<sup>3</sup>, Farheen Raza<sup>2</sup>**ABSTRACT**

**Objective:** This study was performed to check the diagnostic accuracy of MRI in the detection and delineation of sonologically indeterminate adnexal masses as benign or malignant, keeping histopathology as gold standard.

**Study Design:** Cross-sectional study.

**Place and Duration of Study:** This cross-sectional study was conducted at the Department of Diagnostic Radiology of POF Hospital, Wah Cantt, Pakistan, from 1<sup>st</sup> December 2018 to 31<sup>st</sup> May 2019.

**Materials and Methods:** All female patients (15-80 years) with sonographically diagnosed indeterminate adnexal masses, both symptomatic and incidental, were included in the study. Patients who were unfit for surgery and those for whom MRI is contraindicated (cardiac pacemakers, intracranial metal clips, claustrophobic patients, hypersensitivity to contrast) were excluded. Total of 115 patients meeting the inclusion criterion underwent an MRI examination. All patients had undergone surgery in the concerned ward, and a histopathology report was followed. MRI findings were compared with histopathological findings. Data was entered and analysed via SPSS version 26.

**Results:** Mean age of the patients was 48.22±10.5. Out of 115 patients, there were 74 (64.3%) cases related to the uterine mass category, 35 (30.4%) were related to ovarian mass category, and 6 (5.2%) fell in the Extraovarian/Extrauterine mass category. Out of 115 patients, 74 (64.3%) patients had a mass size <3cm, 35 had the size of 3-5 cm (5.2%), and 6 had size >5 cm (5.2%). The sensitivity of MRI was calculated to be 77.14%, specificity was 87.5%, positive predictive value was 72.9%, and negative predictive value was 89.7%.

**Conclusion:** MRI has high sensitivity and specificity in diagnosing adnexal masses and therefore, can serve as a good choice in the delineation of sonographically indeterminate adnexal masses.

**Keywords:** Adnexal Masses, Magnetic Resonance Imaging, Ovarian Masses, Ultrasonography, Uterine Masses.

**How to cite this:** Madiha, Jabeen F, Gul N, Mehmood K, Umbreen S, Raza F. Diagnostic Accuracy of MRI in Delineation of Ultrasonographically Indeterminate Female Adnexal Lesions keeping Histopathology as Gold Standard. *Life and Science*. 2023; 4(1): 51-56. doi: <http://doi.org/10.37185/LnS.1.1.279>

This work is licensed under a Creative Commons Attribution-NonCommercial 4.0 International license.

(<https://creativecommons.org/licenses/by-nc/4.0/>). Non-commercial uses of the work are permitted, provided the original work is properly cited.

<sup>1</sup>Department of Diagnostic Radiology  
Wah International Hospital, Taxilla, Pakistan

<sup>2</sup>Department of Radiology  
PIMS Hospital Islamabad, Pakistan

<sup>3</sup>Department of Radiology  
POF Hospital/ Wah Medical College, Wah Cantt, Pakistan

<sup>4</sup>Department of Neurosurgery  
CMH, Kharian Cantt, Pakistan

Correspondence:

Dr. Nadia Gul  
Department of Radiology  
POF Hospital/ Wah Medical College, Wah Cantt, Pakistan  
E-mail: [mrsnadiagul@gmail.com](mailto:mrsnadiagul@gmail.com)

Funding Source: NIL; Conflict of Interest: NIL

Received: Sep 18, 2022; Revised: Dec 12, 2022

Accepted: Dec 17, 2022

**Introduction**

Pelvic masses are the most prevalent clinical manifestation of pelvic diseases, hence determining their location and classification is critical since it influences therapy options.<sup>1,2</sup> Because of its cost-effectiveness, ease of availability, and high sensitivity, ultrasound is regarded the dominant imaging modality for the examination of pelvic masses.<sup>3,4</sup> Adnexal masses can present symptomatically or might be an incidental finding on routine ultrasound.<sup>5</sup> Since the lesion is either plainly benign or clearly malignant, the majority of women do not require additional imaging.<sup>6</sup> Ultrasound has specificity for detecting adnexal masses and is

capable of differentiating different type of cyst however its specificity for characterizing malignant masses is low.<sup>7</sup> Ultrasound has a specificity of 60-90 percent according to published literature.<sup>8,9,10</sup> However, on Doppler ultrasound, 20% of adnexal masses are categorised as indeterminate.<sup>11</sup> An indeterminate adnexal mass is a complicated mass that cannot be classified as benign or malignant.<sup>12</sup> In a study nodular component without vascularity on ultrasound was found to be one of important indicator of malignancy in indeterminate adnexal cyst.<sup>12</sup>

For a more thorough examination of these indeterminate adnexal masses, a variety of imaging techniques are being examined, with some researchers recommending MRI as the best option. Due to the lack of radiation exposure, multi-planner imaging capabilities, tissue selectivity, and better localization of mass origin, MRI is considered a superior imaging technique.<sup>13</sup>

Another benefit of MRI is that it may identify veins without using intravenous contrast.<sup>13,14</sup> According to reports, MRI has near 100% sensitivity in detecting ovarian masses.<sup>15</sup> It's also a better option for ladies of childbearing age who refuse to have their pelvic mass evaluated with CT or trans-vaginal sonography. MR imaging is accurate in identifying endometric or fatty masses, as well as distinguishing solid from cystic components due to post-contrast enhancement in the former.<sup>16,17</sup> MRI not only accurately diagnoses but also characterizes the adnexal mass as malignant or benign. In one study, gadolinium enhanced MRI with diffusion weighted imaging (DWI) achieved a 93 percent accuracy rate for detecting cancer.<sup>18</sup> According to IOTA LR2 model the indicators of malignancy includes thickened septa, solid component, papillary projections and presence of ascites on ultrasound.<sup>19</sup> However this model is only for ovarian malignancy while MRI can characterize all adnexal masses ovarian or extraovarian. Thick walls (> 3 mm), presence of nodules, vegetations, septations, or papillary projections along with enhancement on post contrast images are all signs of malignancy in an ovarian cyst. Necrosis in a solid ovarian lesion indicates malignancy on MRI.<sup>20,21,22</sup>

In Pakistan, adnexal masses are a prevalent gynaecological issue. Around 5%-10% of women

have needless surgical exploration to rule out malignancy, and only 25% of those who do are found to be cancerous.<sup>23</sup> It has been found that patients with benign masses are sometime subjected to unneeded surgery as a result of questionable ultrasonography findings. This can be avoided by using MRI, which is a reliable inquiry.<sup>24</sup> Study by Farah et al. showed that MRI has a sensitivity and specificity of 94.83 percent and 87.50 percent, respectively.<sup>25</sup> Because almost 10% of women with suspected adnexal tumour in the United States underwent surgical evaluation at some point in their lives, benign masses are an essential consideration.<sup>26</sup>

It has previously been demonstrated in the literature that MRI can accurately diagnose clinically or sonographically ambiguous adnexal masses.<sup>27</sup>

Despite the fact that adnexal masses are relatively common in Pakistan, there is only a limited amount of research on which MR imaging findings are helpful for distinguishing benign from malignant lesions. This is critical since it has an impact on the patient's care. The goal of my research is to see how accurate MR imaging is at detecting, localising, and describing adnexal masses and finally characterizing them as benign or malignant, so that clinicians can make a reasonably clear diagnosis before undergoing an invasive treatment and avoid unnecessary surgical exploration. This classification is crucial because it aids in determining whether the patient will benefit from conservative or radical surgery.

## Materials and Methods

After taking ethical approval, this cross-sectional research was carried out at the Department of Diagnostic Radiology of POF Hospital, Wah Cantt, Pakistan from 1<sup>st</sup> December 2018 to 31<sup>st</sup> May 2019. A sample size of 115 cases was calculated from a sensitivity specificity calculator with a confidence level of 95%, taking the prevalence of adnexal masses as 46%, sensitivity and specificity of MRI being 94.83% and 87.50% with 10% precision.<sup>25</sup> Non-probability consecutive sampling technique was used. All female patients (15-80 years) with sonographically diagnosed indeterminate adnexal masses, both symptomatic and incidental, were included in the study. Patients who were unfit for surgery, and those in whom MRI is contraindicated (cardiac pacemakers, claustrophobic patients, intracranial metallic clips, hypersensitivity to

contrast) were excluded.

**Data Collection Procedure**

Patients satisfying the inclusion criteria after their consent were included in the research. All women underwent pelvic ultrasound by an experienced consultant radiologist using 7 MHz probe after optimally filling the bladder. If required, transvaginal ultrasound after obtaining patient consent was also performed to support the findings. Patients having indeterminate adnexal mass were then further evaluated with contrast-enhanced pelvic MRI. It was performed via SIEMENS MAGNETICOM ERA 1.5 TESLA MRI by a technologist. For MRI, patients were fasting for 6-8 hr, with full bladder and bowel emptied before the examination. Images were attained in supine posture, and multiple sequences were performed, which included with and without fat saturation axial T1 weighted, post-contrast T1 weighted, axial, sagittal and coronal T2 weighted, and coronal STIR. MRI were evaluated by a consultant radiologist having 5 years of experience in the field. All patients have undergone surgery, and specimens were collected and sent for histopathological examination and reported by consultant pathologist. MRI results were correlated with the histopathology report.

**Data Analysis Process**

Data was entered and analysed via SPSS version 26. Descriptive statistics were applied to both qualitative and quantitative data. The sensitivity, specificity, positive predictive value (PPV) and negative predictive value (NPV) of MRI were calculated by a 2x2 contingency table taking histopathology as the gold standard. All results are presented in table 1.

	<b>Malignant on histopathology</b>	<b>Benign on histopathology</b>
Malignant on MRI	True Positive (TP)	False Positive (FP)
Benign on MRI	False Negative (FN)	True Negative (TN)
Sensitivity: TP/ (TP + FN) *100		
Specificity: TN/ (TN + FP) *100		
PPV: TP / (TP + FP) *100		
NPV: TN/ (TN + FN) *100		
Diagnostic accuracy: TP+TN/TP+TN+FP+FN x 100		

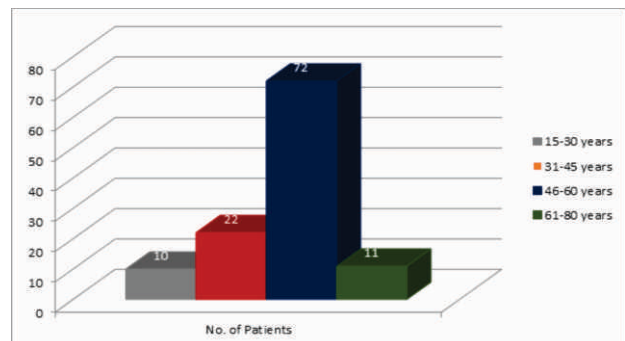
**Results**

Diagnostic accuracy of MRI in diagnosing adnexal masses as benign or malignant taking histopathology

as gold stands shows the sensitivity of MRI 77.14%, specificity was 87.5%, positive predictive value was 72.9 % and negative predictive value was 89.7 % and diagnostic accuracy 84.3% (Table 2).

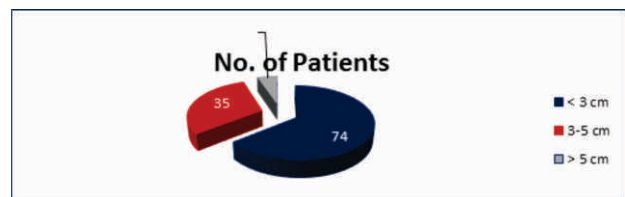
	<b>Malignant on histopathology</b>	<b>Benign on histopathology</b>
Malignant on MRI (test positive)	27 (TP)	10 (FP)
Benign on MRI (test negative)	08 (FN)	70 (TN)
Sensitivity: TP/ (TP + FN) *100		
Sensitivity = 27/ (27+08) x 100 = 77.14%		
Specificity: TN/ (TN + FP) *100		
Specificity = 70/ (70+10) x 100 = 87.5%		
PPV: TP / (TP + FP) *100		
PPV = 27/ (27+10) x 100 = 72.97%		
NPV: TN/ (TN + FN) *100		
NPV = 70/ (70+08) x 100 = 89.74%		
Diagnostic accuracy: TP+TN/TP+TN+FP+FN x 100= 84.3%		

Mean age of the patients was 48.22±10.5. The majority (n=72, 62.6%) of the patients belong to the 40-60 years age group. Detailed stratification based on age group is shown in Figure 1.



**Fig 1: Age-wise distribution of the patients**

Out of 115 patients, there were 74 (64.3%) cases related to the uterine mass category, 35 (30.4%) were related to the ovarian mass category, and 6 (5.2%) fell in the Extraovarian/Extrauterine mass category. Out of 115 patients, 74 (64.3%) patients had a mass size <3cm, 35 had the size of 3-5 cm (5.2%), and 6 had a size >5 cm (5.2%) (Figure 2).



**Fig 2: Frequency of patients on the basis of mass size**

Out of 115 patients, there were 78 (67.8 %) whose MRI diagnosis was benign and the remaining 37 (32.2%) were related to the malignant category (Table 3).

**Table 3: Frequency Statistics of diagnosis on MRI among patients (N =115)**

	Frequency	Percent
Benign	78	67.8
Malignant	37	32.2

Upon histopathology, there were 80 (69.6 %) whose histopathology diagnosis was benign and the remaining 35 (30.4%) were related to the malignant category (Table 4).

**Table 4: Frequency Statistics of diagnosis on Histopathology among patients (N = 115)**

	Frequency	Percent
Benign	80	69.6
Malignant	35	30.4

Detailed sensitivity, and specificity on the basis of size was also performed (Table 5 and 6).

**Table 5: Post Stratification results of diagnosis on MRI on the basis of Size of Mass Category**

Size of Mass		Diagnosis on MRI	Diagnosis on Histopathology		Total
			Benign	Malignant	
< 3cm	Diagnosis on MRI	Benign	42	4	46
		Malignant	8	20	28
3-5cm	Diagnosis on MRI	Benign	22	4	26
		Malignant	2	7	9
> 5cm	Diagnosis on MRI	Benign	6	-	6
		Malignant	-	-	-

**Table 6: Accuracy of MRI based on the mass size**

Size of Mass	Sensitivity	Specificity	PPV	NPV
< 3 cm	83.3%	84%	71.4%	91.3%
3-5 cm	63.6%	91.6%	77.7%	84.6%
> 5 cm	-	100%	-	100%

**Discussion**

Most important step in assessment of adnexal lesion is to figure out whether the mass is benign or malignant.<sup>1</sup> Our study revealed 90 final benign diagnoses, 13 of which were actually normal MRI findings despite a sonographically questioned mass. In our study sensitivity and specificity of contrast enhanced MRI was found to be 77.14% and 87.5%

respectively. The diagnostic accuracy of MRI in our study is 84.3%. Also specificity increased with increase in size of the lesion reaching upto 100% for lesion more than 5cm. our findings are nearly consistent with study carried by Thomassin-Naggara I and his colleagues that shows diagnostic accuracy of MRI for adnexal masses upto 94.6%.<sup>6</sup> In another study conducted by Yasmeen Usmani and colleagues sensitivity, specificity and diagnostic accuracy of MRI in detecting malignant adnexal masses was 75%, 93.9% and 94.8% respectively.<sup>9</sup>

Ultrasound based logistic regression model LR2 was compared with MRI in one study and similar results for the diagnosis of malignant and benign lesions were observed. IOTA LR2 had a sensitivity of 94% as compared to 96% for the MRI. Similarly, 98% specificity was observed for IOTA LR2 as compared to 91% for an MRI. They suggested considering IOTA LR2 as a part of the diagnostic process in conjunction with MRI as the combination showed a 100% sensitivity and specificity.<sup>19</sup>

Thick walls (> 3 mm), presence of nodules, vegetations, septations, or papillary projections are all signs of malignancy in an ovarian cyst. Necrosis in a solid ovarian lesion indicates malignancy.<sup>20,21,22</sup> In our study similar criteria is used for malignant lesion and is confirmed on histopathology. In our study out of 115 patients with sonographically indeterminate adnexal masses, 35 fulfilled the criteria of malignancy on MRI while on histopathology 37 patients had malignancy. DWI and dynamic contrast enhanced MRI can be further helpful in assessment of aggressiveness of tumour and also its prognosis thus helps in deciding treatment plan.<sup>28,29</sup>

A solid mass next to the uterus could be an ovarian mass despite the fact that it is most likely a fibroid. A pedunculated fibroid can be mistaken as adnexal mass on ultrasound. MRI is helpful in such cases. About 10-20% women have fibroids in reproductive age group.<sup>30</sup> Similarly in our study, 64.3% adnexal masses were related to uterine mass category, 35 (30.4%) were related to ovarian mass category and only 6 (5.2%) fell in the Extraovarian/Extrauterine mass category.

Contrast-enhanced MRI had a sensitivity and specificity of 90-100 percent and 80-95% percent, respectively, in diagnosing malignancy when employed for additional investigation of an

ambiguous mass identified on ultrasonography in a prospective sequence.<sup>31,32</sup> Current study also showed specificity of MRI increased with increase in size of lesion reaching up to 100% upon lesion size more than 5 cm.

Thus our study supports all aforementioned studies. There are certain limitations in our study. Contrast enhanced MRI is much expensive than ultrasound and moreover MRI takes much longer time and cannot be performed at bedside. Also some of patients are claustrophobic and refuse the procedure. Due to these facts some clinicians are reluctant to advise contrast enhanced MRI as 1st line investigation. But being non invasive and lack of radiation and having best soft tissue resolution it is superior to ultrasound or CT.

MRI can correctly ascertain the origin of adnexal mass and its characteristics as compared to ultrasound, thus avoiding the unnecessary surgical exploration.

### Conclusion

MRI has high sensitivity and specificity in diagnosing adnexal masses and is a good choice in the delineation of sonologically indeterminate adnexal masses. The use of MRI should be advocated more and more for such conditions as they can be of great help in pre-operative counselling patients for better post-operative management of all such cases.

### REFERENCES

- Szklaruk J, Tamm EP, Choi H, Varavithya V. MR imaging of common and uncommon large pelvic masses. *Radiographics*. 2003; 23: 403-24. doi: 10.1148/rg.232025089
- Reavey J, Vincent K. Chronic Pelvic Pain. *Obstetrics, Gynecology & Reproductive Medicine Journal*. 2021; 32: 8-13. doi: 10.1016/j.ogrm.2021.11.002
- Abinader R, Warsof SL. Benefits and pitfalls of ultrasound in obstetrics and gynecology. *Obstetrics and Gynecology Clinics*. 2019; 46: 367-78. doi: 10.1016/j.ogc.2019.01.011
- Perveen R, Islam AF, Rahman H, Khan RP. Role of Ultrasonography in Evaluation of Pelvic Mass in Female. *Journal of Armed Forces Medical College, Bangladesh*. 2019; 15: 87-9. doi: 10.3329/jafmc.v15i1.48653
- Rockall A, Forstner R. Adnexal Diseases. 2018 Mar; 75-84. doi: 10.1007/s13224-019-01229-z
- Thomassin-Naggara I, Balvay D, Rockall A, Carette MF, Ballester M, Darai E, et al. Added value of assessing adnexal masses with advanced MRI techniques. *BioMed research international*. 2015; 2015. doi: 10.1155/2015/785206
- Smorgick N, Maymon R. Assessment of adnexal masses using ultrasound: a practical review. *International journal of women's health*. 2014; 6: 857-63. doi: 10.2147/IJWH.S47075
- Arezzo F, Loizzi V, La Forgia D, Abdulwakil Kawosha A, Silvestris E, Cataldo V, et al. The role of ultrasound guided sampling procedures in the diagnosis of pelvic masses: a narrative review of the literature. *Diagnostics*. 2021; 11: 2204. doi: 10.3390/diagnostics11122204
- Usmani Y, Bhartiya P, Shukla MK. Role of USG & MRI in Female Pelvic Masses with Histological Correlation in Post-Operative Patients. *Journal of Evolution of Medical and Dental Sciences*. 2020; 9: 3439-44.
- Zhang X, Meng X, Dou T, Sun H. Diagnostic accuracy of transvaginal ultrasound examination for assigning a specific diagnosis to adnexal masses: A meta-analysis. *Experimental and Therapeutic Medicine*. 2020; 20: 1-1. doi: 10.3892/etm.2020.9395
- Ibrahim ZSE. Role of magnetic resonance imaging in the evaluation of sonographically indeterminate adnexal masses. *ALEXMED ePosters*. 2021; 3: 44-5. doi: 10.21608/ALEXPO.2021.94934.1267
- Sadowski EA, Paroder V, Patel-Lippmann K, Robbins JB, Barroilhet L, Maddox E, et al. Indeterminate Adnexal Cysts at US: Prevalence and Characteristics of Ovarian Cancer. *Radiology*. 2018; 287: 1041-9. doi: 10.1148/radiol.2018172271
- Owringi AM, Greer PB, Glide-Hurst CK. MRI-only treatment planning: benefits and challenges. *Physics in Medicine & Biology*. 2018; 63: 05TR01. doi: 10.1088/1361-6560/aaaca4
- Pecoraro M, Messina E, Bicchetti M, Carnicelli G, Del Monte M, Iorio B, et al. The future direction of imaging in prostate cancer: MRI with or without contrast injection. *Andrology*. 2021; 9: 1429-43. doi: org/10.1111/andr.13041
- Sofic A, Husic-Selimovic A, Kativa V, Jahic E, Delic U, Sehic A, et al. Magnetic Resonance Imaging (MRI) and Transvaginal Ultrasonography (TVU) at Ovarian Pain Caused by Benign Ovarian Lesions. *Acta Informatica Medica*. 2018; 26: 15-8. doi: 10.5455/aim.2018.26.15-18
- Kaur K, Dwivedi P, Singh S, Nagar A, Alvi S. DIAGNOSTIC ACCURACY OF ADNEXAL MASSES THROUGH MAGNETIC RESONANCE IMAGING IN CORRELATION WITH HISTOPATHOLOGY. *European Journal of Molecular & Clinical Medicine*. 2022; 9: 721-41.
- Assouline V, Dabi Y, Jalaguier-Coudray A, Stojanovic S, Millet I, Reinhold C, et al. How to improve O-RADS MRI score for rating adnexal masses with cystic component? *European Radiology*. 2022; 32: 5943-53. doi: 10.1007/s00330-022-08644-3
- Rotili A, Trimboli RM, Penco S, Pesapane F, Tantrige P, Cassano E, et al. Double reading of diffusion-weighted magnetic resonance imaging for breast cancer detection. *Breast cancer research and treatment*. 2020; 180: 111-20. doi: 10.1007/s10549-019-05519-y
- Shimada K, Matsumoto K, Mimura T, Ishikawa T, Munechika J, Ohgiya Y, et al. Ultrasound-based logistic regression model LR2 versus magnetic resonance imaging for discriminating between benign and malignant adnexal masses: a prospective study. *International Journal of Clinical Oncology*. 2018; 23: 514-21. doi: 10.1007/s10147-017-1222-y

20. Amante S, Santos F, Cunha TM. Low-grade serous epithelial ovarian cancer: a comprehensive review and update for radiologists. *Insights into Imaging*. 2021; 12: 1-2. doi: 10.1186/s13244-021-01004-7
21. Avesani G, Caliolo G, Gui B, Petta F, Panico C, La Manna V, et al. Pearls and Potential Pitfalls for Correct Diagnosis of Ovarian Cystadenofibroma in MRI: A Pictorial Essay. *Korean Journal of Radiology*. 2021; 22: 1809-21. doi: 10.3348/kjr.2020.1312
22. El-Wekil AM, Abdullah MS, El-Kholy SS. The role of MRI in the differentiation between benign and malignant ovarian lesions. *Menoufia Medical Journal*. 2019; 32: 106-11. doi: 10.4103/mmj.mmj\_548\_17
23. Kumar S, Singh R, Kumar R, Singh A, Netam S, Patre V, et al. Magnetic Resonance Imaging of Sonographically Indeterminate Adnexal Masses: A Reliable Diagnostic Tool to Detect Benign and Malignant Lesion. *International Journal of Scientific Study*. 2017; 5: 200-5.
24. Spencer JA, Ghattamaneni S. MR imaging of the sonographically indeterminate adnexal mass. *Radiology*. 2010; 256: 677-94. doi: 10.1148/radiol.10090397
25. FZ MAI. Diagnostic accuracy of Doppler Ultrasonography and Contrast Enhanced MRI in differentiating Malignant from Benign adnexal masses. *Journal of Islamabad Medical & Dental College*. 2015; 4: 106–9.
26. Cole CJ, Russell KS, Han JJ. The Role of Imaging in the Evaluation of Adnexal Masses. *Current Women's Health Reviews*. 2017; 15: 12–22. doi: 10.2174/1573404814666171205102008
27. D'Ambrosio V, Brunelli R, Musacchio L, Del Negro V, Vena F, Boccuzzi G, et al. Adnexal masses in pregnancy: an updated review on diagnosis and treatment. *Tumori journal*. 2021; 107: 12-6. doi: 10.1177/0300891620909144
28. Engbersen MP, Van't Sant I, Lok C, Lambregts DM, Sonke GS, Beets-Tan RG, et al. MRI with diffusion-weighted imaging to predict feasibility of complete cytoreduction with the peritoneal cancer index (PCI) in advanced stage ovarian cancer patients. *European Journal of Radiology*. 2019; 114: 146-51. doi: 10.1016/j.ejrad.2019.03.007
29. Lindgren A, Anttila M, Arponen O, Rautiainen S, Könönen M, Vanninen R, et al. Prognostic value of preoperative dynamic contrast-enhanced magnetic resonance imaging in epithelial ovarian cancer. *European Journal of Radiology*. 2019; 115: 66–73. doi: 10.1016/j.ejrad.2019.03.023
30. Khan AT, Shehmar M, Gupta JK. Uterine fibroids: current perspectives. *International journal of women's health*. 2014; 6: 95-114. doi: 10.2147/IJWH.S51083
31. Bo X, Chen E, Wang J, Nan L, Xin Y, Wang C, et al. Diagnostic accuracy of imaging modalities in differentiating xanthogranulomatous cholecystitis from gallbladder cancer. *Annals of translational medicine*. 2019; 7: 627. doi: 10.21037/atm.2019.11.35
32. Vollenbrock SE, Voncken FEM, van Dieren JM, Lambregts DMJ, Maas M, Meijer GJ, et al. Diagnostic performance of MRI for assessment of response to neoadjuvant chemoradiotherapy in oesophageal cancer. *Journal of British Surgery*. 2019; 106: 596–605. doi: 10.1002/bjs.11094

.....