

## ORIGINAL ARTICLE

**Impact of Short-Term Arsenic Exposure on Hormonal Balance and Fibrosis in Sprague Dawley Rats**Amaidah Mir<sup>1\*</sup>, Urfa Zaryab Mir<sup>2</sup>, Warda Hussain<sup>3</sup>, Ayesha Irfan<sup>4</sup>, Hammad Ahmed Butt<sup>5</sup>, Urwa Sarwar<sup>6</sup>**ABSTRACT**

**Objective:** To evaluate the toxic effects of arsenic exposure on the female reproductive tract and endocrine system.

**Study Design:** A laboratory-based experiment.

**Place and Duration of Study:** The study was carried out at the Laboratory of the National Institute of Health (NIH) Islamabad, Pakistan from 1<sup>st</sup> January 2019 to 4<sup>th</sup> January 2020.

**Methods:** non-probability convenient sampling technique was employed and 60 female healthy Sprague Dawley rats were included in the study at the National Institute Islamabad. Animals were randomly allocated into control and experimental groups (n=30 each). In the first week, animals were acclimatized to the animal house of the College of Physicians and Surgeons Pakistan. In the second week, the control and experimental groups were given 10 ml of distilled water by oral gavage daily and 4µg of sodium arsenite dissolved in 10 ml of distilled water daily for two weeks respectively. After the experimental period, animals were taken to the animal lab of the National Institute of Health Islamabad for blood sampling and tissue dissection. Rats were euthanized by chloroform inhalation and blood was drawn by single intracardiac puncture and stored in clot activator vials at 4 °C for further workup. The female reproductive tract was dissected, and the tissue was stored in 10 % formalin for histological studies. Serum Gonadotropin-releasing hormone (GnRH) levels were assessed via the Enzyme-Linked Immunosorbent Assay (ELISA) method. Whereas histological effects of arsenic were observed under a microscope by tissue processing and staining with Masson trichrome stain. Mean ± SD of serum GnRH levels and percentage of fibrosis in uterine tissue of control and experimental groups were evaluated by the software Statistical Package for Social Sciences version 22.0. Comparison of means evaluated by Student T-test. The significant *p-value* was ≤ 0.05.

**Results:** The experimental group showed significant elevation of serum GnRH levels and fibrotic changes with high collagen deposition (*p* ≤ 0.05).

**Conclusion:** Exposure to arsenic via contaminated drinking water is disruptive for the female reproductive tract and endocrine system.

**Keywords:** Arsenic, ELISA, Endometrial Fibrosis, GnRH.

**How to cite this:** Mir A, Mir UZ, Hussain W, Irfan A, Butt HA, Sarwar U. Impact of Short-Term Arsenic Exposure on Hormonal Balance and Fibrosis in Sprague Dawley Rats. *Life and Science*. 2024; 5(2): 187-192. doi: <http://doi.org/10.37185/LnS.1.1.642>

This work is licensed under a Creative Commons Attribution-NonCommercial 4.0 International license. (<https://creativecommons.org/licenses/by-nc/4.0/>). Non-commercial uses of the work are permitted, provided the original work is properly cited.

<sup>1</sup>Department of Anatomy/Biochemistry<sup>2</sup>/Pharmacology<sup>3</sup>/Pathology<sup>6</sup>  
CMH Kharian Medical College, Kharian, Pakistan

<sup>3</sup>Department of Pathology  
Nawaz Sharif Medical College Gujrat, Pakistan

<sup>4</sup>Department of Anatomy  
CMH Multan Institute of Medical Science, Multan, Pakistan

Correspondence:

Dr. Amaidah Mir

Assistant Professor, Anatomy

CMH Kharian Medical College, Kharian, Pakistan

E-mail: [amaidahmir@gmail.com](mailto:amaidahmir@gmail.com)

Funding Source: NIL; Conflict of Interest: NIL

Received: Oct 22, 2023; Revised: Feb 18, 2024

Accepted: Mar 16, 2024

**Introduction**

Arsenic is a well-known toxin, and its measurable quantities are present in our soil, air, and underground water table. Millions of people worldwide are affected by the usage of contaminated drinking water via heavy metals including arsenic and the majority of them are Asians.<sup>1</sup> WHO has warned that the arsenic safety limits in potable water should be less than 10 µg/l.<sup>2</sup> Use of arsenic in cultivation (as a pesticide) and in

many industries (e.g., glass manufacturing, wood preservation, and in car batteries as alloys) and lack of awareness and water purification systems in developing and under-developed countries, these anthropogenic sources are increasing the amount of arsenic in our potable water beyond the safety limits.<sup>3</sup> The toxicity of arsenic depends upon its oxidative state. Arsenite (trivalent form, <sup>+3</sup>) being more stable, absorbable, and highly reactive is more poisonous than arsenate (pentavalent form, <sup>+5</sup>).<sup>4</sup> Chronic exposure to arsenic has been proven to be teratogenic, mutagenic, and carcinogenic.<sup>5</sup> It also causes disruption of the respiratory system, central nervous system, endocrine system, cardiovascular system and reproductive system of humans and animals.<sup>6,7</sup>

The reproductive system of females has ovaries, fallopian tubes, a uterus, a cervix and a vagina. This system is regulated by specific hormones e.g., gonadotropin-releasing hormone (GnRH), gonadotropins (luteinizing hormone and follicle-stimulating hormone), Estrogen, and Progesterone.<sup>8</sup> GnRH is released from the hypothalamus and it controls sexual maturity and reproduction by stimulating the production and release of LH and FSH. Both these hormones are collectively called gonadotropins for acting upon the gonads. FSH stimulates the synthesis of oocytes in female ovaries. While LH (luteinizing hormone) helps in ovulation and the production of estrogen from the ovaries. The cyclic and pulsatile release of FSH and LH in female rats thus regulate the estrous cycle and endometrial milieu. Estrogen maintains the uterine epithelium and prepares the uterus for conception. Whereas progesterone sustains the pregnancy and prevents abortions or premature birth. FSH and LH, in return, suppress GnRH via a negative feedback mechanism. Thus, GnRH indirectly controls all the other female reproductive hormones and regulates the female reproductive system.

Data from previous studies has highlighted that prolonged exposure to arsenic in females leads to disruption of various female reproductive hormones and causes congenital malformations, low birth weight babies, abortions, and still births. These adverse effects have been observed in rodent models also.<sup>9,10</sup>

Histological studies revealed that arsenic promotes fibrosis of lungs, liver, and kidneys tissue but minimal data is available regarding such pathological changes in the female reproductive tract.<sup>11-13</sup> This study, hence designed to evaluate the histological effects of a minimal dose of arsenic given for a shorter time on uterine tissue along with GnRH levels in Sprague Dawley rats.

## Methods

The study was carried out at the Laboratory of the National Institute of Health (NIH) Islamabad, Pakistan from 1<sup>st</sup> January 2019 to 4<sup>th</sup> January 2020 in which we took 60 inbred healthy female Sprague Dawley rats having a body weight of 200-250 g. Animals with any disease or visible deformity were excluded from the study. Ethical approval for this study was obtained by the Research Ethical Committee of the College of Physicians and Surgeons (CPSP), Islamabad Pakistan vide letter no: CPSP/RTMC/ANT-2015-047-37 held on dated: 5<sup>th</sup> February 2019 according to the guidelines of National Institute of Health Guide for Care and Use of Laboratory Animals (Publication # 85-23, revised in 1985). Rats were kept in the animal house of the College of Physicians and Surgeons Pakistan (CPSP) regional center in Islamabad. Out of them, 30 rats were kept in the control group (A) and 30 were kept in the experimental group (B). Rats were habituated for one week before any intervention under optimum room temperature (25±2°C), 12 hours of day and night cycle, and ~60% humidity. Throughout the experiment, the animals of both groups were on standard diet diets with free access to water. After the habituation period, the control group animals received 10 ml of distilled water administered via oral gavage method every day for two weeks and experimental animals received 4µg of sodium arsenite dissolved in 10ml of pure distilled water via oral gavage method every day for two weeks. Arsenic was purchased from Hamza Enterprises Sadder Rawalpindi (prepared by LAB CHEM lot # 1406).

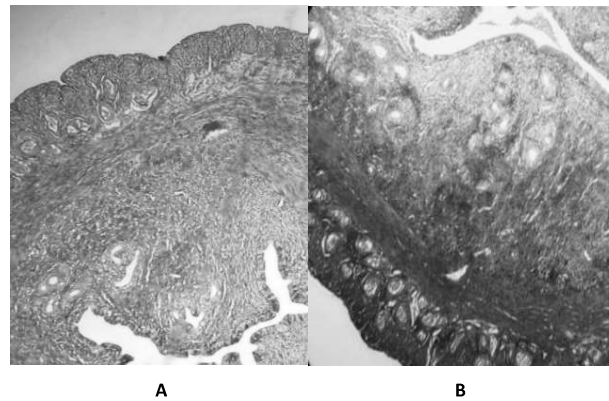
After 14 days, rats were taken to the animal lab of NIH Islamabad for blood sampling and tissue dissection. Rats were anesthetized by chloroform inhalation. The blood was drawn by a single intra-cardiac puncture. Before applying the standard centrifugation technique, clot activator vials were

used to store the blood at a temperature 4-8 °C and let it sit for 30 minutes. For serum separation, blood was centrifuged at 2000 g for approximately 10 minutes then stored in aseptic and disposable Eppendorf tubes at a temperature of -80°C for hormonal analysis. Levels of serum GnRH were evaluated by using the commercially available specific rat ELISA kits.<sup>14</sup> ABclonal rat ELISA kit for GnRH colorimetric assay was purchased from Biodiagnostic Resources Commercial market Rawalpindi. The kit had Cat # RK14465, a range of detection of 15.6-1000 pg/ml, and sensitivity of 7.8 pg/ml.

Tissue samples of the uterus were collected during dissection and fixed in 10% formalin solution. To make the paraffin blocks the traditional method of tissue processing was used. Tissue slices of 5-7 microns were taken. Masson trichrome stain was used to analyze the fibrotic changes in collagen fibers of connective tissue under a light microscope at 40X. To evaluate the endometrial fibrosis, on each slide five random fields were taken. The ratio of endometrial fibrotic areas was assessed by using Image J software.

SPSS version 22.0 was used for data analysis. Mean ±

SD values of serum GnRH levels and degree of fibrosis in uterine tissue of both A and B groups were evaluated. Comparison of the means of endometrial fibrosis and hormonal levels of both groups were estimated by the Independent Student T-test. *p*-value of ≤0.05 was taken as significant in this study.



**Fig.1: Masson's trichrome staining on uterine sections. Group A (control) fine collagen fibers are seen. Group B (experimental): deposition of coarse collagen fibers in the lamina propria. Magnification: 40X**

**Table-1: Mean ± SD values of Percentage Area of collagen in uterus and GnRH values of control and experimental group**

Parameters	Group A (n = 30) Mean ± SD	Group B (n = 30) Mean ± SD	<i>p</i> -value
Percentage Area of collagen in the uterus (%)	8.06 ± 7.38	12.32 ± 11.03	< 0.05
GnRH values (pg/ml)	64.25 ± 14.77	298.02 ± 35.45	< 0.05

**Results**

Under the microscope, Masson trichrome staining showed that endometrial morphology was intact in the rats of the control group. The collagen fibers in the endometrium of control rats were blue and orderly arranged while the deposition of endometrial collagen fibers was quite increased in experimental rats. In Image J software the percentage area of collagen fibers per unit area in a rat's uterus (%) was calculated from group A and group B. There was a significant difference in the mean ± SD values of the percentage area of endometrial collagen deposition between

control and experimental animals (*p* < 0.05).

The comparative results of GnRH levels in control and experimental groups are also shown in table # 1. In comparison with the control group, the animals in experimental group showed a significant increase in serum GnRH levels with a *p*-value < 0.05.

**Discussion**

Reproductive tract abnormalities have become a global issue. According to a WHO report, more than 45 million couples are suffering from infertility all around the world. The data from medical surveys and the standard fertility workups concluded that 30% of these infertile couples have no known cause

of infertility.<sup>15</sup> Heavy metals exposure has been proven to be one of the most dangerous causes of reproductive tract abnormalities.<sup>16</sup> Very strong evidence proves that exposure to arsenic disturbs the normal physiology and histology of the reproductive tract by altering the levels of female reproductive hormones.<sup>17,18</sup>

Results of this study have indicated a significant elevation of serum GnRH levels after arsenic exposure in the interventional group (group B) as compared to the control group (group A) with *p-value* ≤ 0.005. The possible mechanism of raised GnRH levels in experimental rats is due to the loss of negative feedback control of FSH and LH on GnRH secretions after arsenic exposure. According to the study of Zhiwei Guo, exposure to different doses of arsenic raised the levels of GnRH and reduced levels of FSH and LH due to a lack of negative feedback of FSH and LH on GnRH.<sup>19</sup>

The study of Shamima Khatun in 2018 also revealed the same conclusion that 1mg/100 g of arsenic given for 8 days significantly suppresses the normal levels of serum FSH, LH, and estrogen hormones.<sup>20</sup> These results favor the hypothesis of inhibition of negative feedback effects of these hormones on GnRH levels by arsenic exposure.

The exact cause of arsenic toxicity is not known but, scientific studies proposed that arsenic being a heavy metal releases free electrons in the body. These free electrons damage the structure and functions of cellular proteins, cell organelles, and DNA.<sup>15</sup> Arsenic binds with the sulfhydryl group of cellular proteins and alters their structure and function. Arsenic also induces epigenetic changes in DNA by altering the DNA methylation process. Thus, arsenic induces inflammation and cellular damage.<sup>21,22</sup> Felor Zargari in 2022 concluded that the oxidative stress induced by arsenic disrupts the normal levels of reproductive hormones, dysregulates spermatogenesis and oogenesis, and leads to infertility.<sup>15</sup>

This study highlighted the fibrotic changes in the endometrium induced by arsenic which is seen under a microscope as increased production of collagen and other extracellular matrix components and thickening and damage of the internal lining of the uterus.<sup>23</sup> The exact mechanism of endometrial

fibrosis by arsenic is still unknown but here are a few possible explanations.

Tissue fibrosis occurs when extracellular matrix (ECM) is extremely deposited in the vicinity of edematous and damaged tissue leading to increased deposition of collagen fibers by increased levels of transforming growth factor (TGF)- $\beta$ .<sup>24</sup>

Arsenic can interfere with the hormonal regulation of the endometrium, altering the expression of estrogen and progesterone receptors and their downstream targets e.g., matrix metalloproteinase (MMPs) and transforming growth factor (TGF)- $\beta$ . These factors are involved in the balance between tissue remodeling and fibrosis.<sup>25</sup>

Besides all arsenic increases the expression of fibrotic markers including fibronectin,  $\alpha$ -smooth muscle actin, and Collagen I. In response to this due to fibrosis neutrophilic enzymes like matrix metalloproteinase-2 and metalloproteinases are released that can damage the tissue very easily.<sup>11</sup>

The results of this study may have a positive impact on human health as the concentrations of arsenic tested in this study completely overlap the environmental levels recorded.

## Conclusion

Exposure to arsenic-polluted water is hazardous to the reproductive tract and endocrine system of females.

## Limitations of Study

- Financial constraints
- Handling class 1 poison (arsenic) required a high level of vigilance.
- Moreover, applying similar study designs on humans exposed to arsenic contaminated drinking water will require a certain degree of amendments in the methodology.

## Acknowledgement

Professor Muhammad Younas Khan (late).

## REFERENCES

1. Chen QY, Costa M. Arsenic: a global environmental challenge. Annual Review of Pharmacology and Toxicology. 2021; 61: 47-63. doi: 10.1146/annurev-pharmtox-030220-013418
2. Sinha D, Prasad P. Health effects inflicted by chronic low-level arsenic contamination in groundwater: A global public health challenge. Journal of Applied Toxicology. 2020; 40: 87-131. doi: 10.1002/jat.3823

3. Monteiro De Oliveira EC, Caixeta ES, Santos VSV, Pereira BB. Arsenic exposure from groundwater: environmental contamination, human health effects, and sustainable solutions. *Journal of Toxicology and Environmental Health*. 2021; 24: 119-35. doi: 10.1080/10937404.2021.1898504
4. Manirethan V, Raval K, Balakrishnan RM. Adsorptive removal of trivalent and pentavalent arsenic from aqueous solutions using iron and copper impregnated melanin extracted from the marine bacterium *Pseudomonas stutzeri*. *Environmental Pollution*. 2020; 257: 113576. doi: 10.1016/j.envpol.2019.113576
5. Palma-Lara I, Martínez-Castillo M, Quintana-Pérez J, Arellano-Mendoza M, Tamay-Cach F, Valenzuela-Limón O, et al. Arsenic exposure: A public health problem leading to several cancers. *Regulatory Toxicology and Pharmacology*. 2020; 110: 104539. doi: 10.1016/j.yrtph.2019.104539
6. Muzaffar S, Khan J, Srivastava R, Gorbatyuk MS, Athar M. Mechanistic understanding of the toxic effects of arsenic and warfare arsenicals on human health and environment. *Cell Biology and Toxicology*. 2023; 39: 85-110. doi: 10.1007/s10565-022-09710-8
7. Martínez-Castillo M, García-Montalvo EA, Arellano-Mendoza MG, Sánchez-Peña LdC, Soria Jasso LE, Izquierdo-Vega JA, et al. Arsenic exposure and non-carcinogenic health effects. *Human & Experimental Toxicology*. 2021; 40: S826-50. doi: 10.1177/09603271211045955
8. Shao S, Zhao H, Lu Z, Lei X, Zhang Y. Circadian rhythms within the female HPG axis: from physiology to etiology. *Endocrinology*. 2021; 162: bqab117. doi: 10.1210/ endocr/ bqab117
9. Shih YH, Bryan MS, Argos M. Association between prenatal arsenic exposure, birth outcomes, and pregnancy complications: An observational study within the National Children's Study cohort. *Environmental research*. 2020; 183: 109182. doi: 10.1016/j.envres.2020.109182
10. Souza ACF, Ervilha LOG, Coimbra JLP, Bastos DSS, Guimarães SEF, Machado-Neves M. Reproductive disorders in female rats after prenatal exposure to sodium arsenite. *Journal of Applied Toxicology*. 2020; 40: 214-23. doi: 10.1002/jat.3897
11. Chang YW, Singh KP. Arsenic induces fibrogenic changes in human kidney epithelial cells potentially through epigenetic alterations in DNA methylation. *Journal of Cellular Physiology*. 2019; 234: 4713-25. doi: 10.1002/jcp.27244
12. Wang W, Zheng F, Zhang A. Arsenic-induced lung inflammation and fibrosis in a rat model: Contribution of the HMGB1/RAGE, PI3K/AKT, and TGF- $\beta$ 1/SMAD pathways. *Toxicology and Applied Pharmacology*. 2021; 432: 115757. doi: 10.1016/j.taap.2021.115757
13. Tao Y, Qiu T, Yao X, Jiang L, Wang N, Jia X, et al. Autophagic-CTSB-inflammasome axis modulates hepatic stellate cells activation in arsenic-induced liver fibrosis. *Chemosphere*. 2020; 242: 124959. doi: 10.1016/j.chemosphere.2019.124959
14. Pan F, Du H, Tian W, Xie H, Zhang B, Fu W, et al. Effect of GnRH immunocastration on immune function in male rats. *Frontiers in Immunology*. 2023; 13: 1023104. doi: 10.3389/fimmu.2022.1023104
15. Zargari F, Rahaman MS, KazemPour R, Hajirostamlou M. Arsenic, oxidative stress and reproductive system. *Journal of Xenobiotics*. 2022; 12: 214-22. doi: 10.3390/jox 12030016
16. Bhardwaj JK, Paliwal A, Saraf P. Effects of heavy metals on reproduction owing to infertility. *Journal of Biochemical and Molecular Toxicology*. 2021; 35: e22823. doi: 10.1002/jbt.22823
17. Mondal R, Mukhopadhyay A, Chattopadhyay A, Bandyopadhyay A, Mukhopadhyay PK. Ovarian follicular atresia and uterine toxicity after subchronic oral exposure of postpubertal rats to sodium arsenite. *Comparative Clinical Pathology*. 2022; 31: 597-612. doi: 10.1007/s00580-022-03358-w
18. Chen P, Luo Q, Lin Y, Jin J, Hu KL, Wang F, et al. Arsenic exposure during juvenile and puberty significantly affected reproductive system development of female SD rats. *Ecotoxicology and Environmental Safety*. 2022; 242: 113857. doi: 10.1016/j.ecoenv.2022.113857
19. Guo Z, Guo H, Xia Y. Effects on endocrine system of female rats exposed to chronic arsenic. *Wei Sheng yan jiu*. *Journal of Hygiene Research*. 2011; 40: 178-9.
20. Khatun S, Maity M, Perveen H, Dash M, Chattopadhyay S. *Spirulina platensis* ameliorates arsenic-mediated uterine damage and ovarian steroidogenic disorder. *Facets*. 2018; 3: 736-53. doi: 10.1139/facets-2017-0099
21. Tam LM, Wang Y. Arsenic exposure and compromised protein quality control. *Chemical research in toxicology*. 2020; 33: 1594-604. doi: 10.1021/acs.chemrestox.0c00107
22. Nava-Rivera LE, Betancourt-Martínez ND, Lozoya-Martínez R, Carranza-Rosales P, Guzmán-Delgado NE, Carranza-Torres IE, et al. Transgenerational effects in DNA methylation, genotoxicity and reproductive phenotype by chronic arsenic exposure. *Scientific reports*. 2021; 11: 8276. doi: 10.1038/s41598-021-87677-y
23. Zota AR, Geller RJ, Calafat AM, Marfori CQ, Baccarelli AA,

- Moawad GN. Phthalates exposure and uterine fibroid burden among women undergoing surgical treatment for fibroids: a preliminary study. *Fertility and sterility*. 2019; 111: 112-21. doi: 10.1016/j.fertnstert.2018.09.009
24. Garcia Garcia JM, Vannuzzi V, Donati C, Bernacchioni C, Bruni P, Petraglia F. Endometriosis: cellular and molecular mechanisms leading to fibrosis. *Reproductive Sciences*. 2023; 30: 1453-61. doi: 10.1007/s43032-022-01083-x
25. Vigano P, Candiani M, Monno A, Giacomini E, Vercellini P, Somigliana E. Time to redefine endometriosis including its pro-fibrotic nature. *Human Reproduction*. 2018; 33: 347-52. doi: 10.1093/humrep/dex354

**Authors Contribution**

**AM:** Idea conception, study designing, data collection, data analysis, results and interpretation  
**UZ:** Data collection, data analysis, results and interpretation, manuscript writing, and proofreading  
**WH:** Data analysis, results and interpretation, manuscript writing, and proofreading  
**AI:** Study designing, manuscript writing, and proofreading  
**HAB:** Data collection, data analysis, results and interpretation  
**US:** Data collection, data analysis, results and interpretation, manuscript writing, and proof reading

.....