

## ORIGINAL ARTICLE

**Hepatoprotective Effect of Aqueous Neem Leaves Extract on Hepatocytes and Nuclear Diameter of Albino Wistar Rats Induced with Erythromycin Toxicity**Nausheen Jamshed<sup>1</sup>, Iffat Raza<sup>1\*</sup>, Mehwish Razzaq<sup>1</sup>, Naureen Jamshed<sup>2</sup>, Aaqiba Rasheed<sup>3</sup>, Lubna Faisal<sup>4</sup>**ABSTRACT**

**Objective:** To evaluate the hepatoprotective effects of Neem leaves extract on hepatocyte and nuclear diameters of Albino Wistar rats induced by erythromycin hepatotoxicity.

**Study Design:** Laboratory-based Experimental study.

**Place and Duration of Study:** The study was carried out at the Department of Anatomy and Animal House of Baqai Medical University (BMU) in Karachi, Pakistan from January 2019 to March 2019.

**Methods:** A total of 80 Albino Wistar rats were divided equally into 4 groups. The control group was marked as Group A with no interventions. In Group B only erythromycin was administered. For Group C both erythromycin and aqueous Neem leaf Extract were given and for Group D only aqueous neem leaf was given. Animals were sacrificed and the liver weight of Albino Wistar rats was measured.

**Results:** It was observed that rats of experimental control group A noticed no significant change in hepatocytes  $13.19 \pm 0.44 \mu\text{m}$  and nuclear diameters  $7.18 \pm 0.28 \mu\text{m}$  (Figure.1) as this group had no intervention received. In group B hepatocyte diameter markedly increased by  $16.54 \pm 0.6 \mu\text{m}$  and a decrease in nuclear diameter of  $5.20 \pm 0.30 \mu\text{m}$  ( $p < 0.01$ ) with loss of architecture, ballooning, and edematous changes (Figure.2, 3 and 4) was observed as this group received only erythromycin while group C received both erythromycin and aqueous Neem leaf extract showed histological architecture disrupted to some extent and hepatocytes  $14.49 \pm 80 \mu\text{m}$  and nuclear diameter  $6.13 \pm 0.17 \mu\text{m}$  were started to improve its normal sizes (Figure.5). Group D observed no significant changes in hepatocytes  $13.0 \pm 0.52 \mu\text{m}$  and nuclear diameters  $7.14 \pm 0.30 \mu\text{m}$  as this group only received aqueous neem leaf extract (Figure.6).

**Conclusion:** According to the current study, Erythromycin exerts oxidative stress and Changes in hepatocytes and nuclear diameters were noticeably improved by aqueous neem leaf extract, which is a powerful antioxidant.

**Keywords:** Erythromycin, Hemorrhages, Hepatocytes, Oxidative Stress.

**How to cite this:** Jamshed N, Raza I, Razzaq M, Jamshed N, Rasheed A, Faisal L. Hepatoprotective Effect of Aqueous Neem Leaves Extract on Hepatocytes and Nuclear Diameter of Albino Wistar Rats Induced with Erythromycin Toxicity. *Life and Science*. 2024; 5(2): 228-236. doi: <http://doi.org/10.37185/LnS.1.1.572>

This work is licensed under a Creative Commons Attribution-NonCommercial 4.0 International license. (<https://creativecommons.org/licenses/by-nc/4.0/>). Non-commercial uses of the work are permitted, provided the original work is properly cited.

<sup>1</sup>Department of Anatomy  
Karachi Institute of Medical Sciences, Karachi, Pakistan

<sup>2</sup>Institute of Population and Health Sciences  
Queen Mary University London, England

<sup>3</sup>Department of Anatomy  
Islam Medical and Dental College, Sialkot, Pakistan

<sup>4</sup>Department of Anatomy  
Liaquat National Hospital and Medical college, Karachi, Pakistan

Correspondence:

Dr. Iffat Raza

Associate Professor, Anatomy

Karachi Institute of Medical Sciences, Karachi, Pakistan

E-mail: [razaiffat2@gmail.com](mailto:razaiffat2@gmail.com)

Funding Source: NIL; Conflict of Interest: NIL

Received: Oct 12, 2023; Revised: Jan 23, 2024

Accepted: Mar 31, 2024

**Introduction**

The liver is an essential organ for maintaining the body's homeostasis. The liver's primary function is to cleanse the blood from the gastrointestinal system before directing it to the rest of the body. It metabolizes drugs and has an incredible capacity to detoxicate hazardous chemicals.<sup>1</sup> The liver directs physiological activities in the body such as secretion, metabolism, and storage, and regulates glucose

levels through glycogen storage.<sup>2</sup> Furthermore, the liver secretes bile, which reaches the intestines. It also metabolizes proteins that are required for clotting factors and various processes.<sup>3</sup>

Hepatocytes are usually arranged as cords of one or two cells which are separated by sinusoids under the microscope. Sinusoids are channels composed of hepatocyte plates. Cords of hepatocytes have the potential to regenerate. Hepatocytes are polygonal in shape with eosinophil-rich cytoplasm and a central nucleus. The normal mean hepatocyte diameter of albino Wistar rats was about 11-13 micrometers and the mean nuclear diameter was 6-7 micrometers.<sup>4</sup>

Erythromycin (EM) is now gaining attention for its unique anti-inflammatory properties. It is an antibiotic that belongs to the macrolide group. It is a low-cost and widely accessible generic medication.<sup>5</sup> It has been used against many infectious diseases for over 50 years.<sup>6</sup>

Erythromycin can be used to treat a variety of illnesses, including tonsillitis bronchopneumonia, urinary tract infections, arthritis, mastitis, and lymphadenitis. In addition to infections caused by a variety of organisms including Chlamydia, Staphylococcus, Haemophilus, Streptococcus, Pasteurella, and Mycoplasma.<sup>7</sup> However, when erythromycin stearate was administered orally to rats for 14 days at a daily dose of 100 mg/kg, it caused significant liver damage and hepatotoxicity.<sup>8</sup>

Azadirachta indica (Neem) is considered the king of the medicinal kingdom. In general, it has been used for many years and continues to be used for medicinal and therapeutic purposes. Plant extracts or secondary metabolites have served as antioxidants in phyto-therapeutic drugs to protect against various diseases for a considerable period.<sup>9</sup> Neem leaves contain a variety of compounds, including triterpenoids (such as 6 alphahydroxi-azadiradione and di-hydronimocinol), sesquiterpene lactones such as Azadirachtin limonoid (C35 H44 O16) and its derivatives, nimbin and some of its derivative's quercetin, B-sitoesterol, and quercitrin.<sup>10</sup>

Limonoids are one of the most important bioactive compounds, the other main components are steroids alkaloids, ketones flavonoids, carotenoids

phenolic compounds, sulsin, salanin, valasin, meliasin, nimbin, gedusin etc.<sup>11</sup> Bioactive components such as glycosides sterol, peptides, alkaloids, flavonoids, phenols, and tannins contain medicinal properties.<sup>12</sup>

Neem extract is very effective in the prevention of many diseases. Its multiple benefits contribute to disease-healing effects. Neem extracts have a strong antioxidant activity because they prevent the production of free radical scavengers due to their rich source of antioxidant compounds, i.e. azadiritine and nimbolide.<sup>13</sup> Neem extract also has anticancer properties by regulating cell signaling pathways. Studies show that in the inflammatory process nimbidin inhibits the function of macrophages and neutrophils.<sup>14</sup>

Because of its antioxidant activity, neem extract is known to have hepatoprotective effects in paracetamol intoxication. Its extract improves mononuclear phagocytic systems, immune-stimulating effect, and hepatoprotection. The liver Hepatoprotective dose of Neem extract is 500mg/kg of body weight which decreases hepatocellular necrosis, protects against liver damage, and restores normal liver function.<sup>15</sup>

In a recent study to assess the hepatoprotective effects of Neem leave extract on hepatocyte and nuclear diameters of Albino Wistar rats induced by erythromycin hepatotoxicity.

## Methods

This experimental research was conducted at the Department of Anatomy and Animal House of Baqai Medical University (BMU) in Karachi, Pakistan from January 2019 to March 2019 after the approval from the Ethical Review Committee of the university held on 11<sup>th</sup> January 2017 vide letter no: BMU-EC/2016-05. In a controlled environment at 30 C with an average of 14 days and 10 nights of cycles, 80 male Albino Wistar rats, 13–14 weeks old, weighing 180–200g, were procured from an animal house. The rats were kept in plastic cages with five rats per cage. Standard food and water were provided to the rats. Before the trial began, it was ensured that the rats had been acclimatized for around 10 days. Erythromycin tablets (erythrocin R) 500 mg made by Indus Pharma from the pharmacy in Malir Cantt Karachi were purchased. At Pakistan Council

Scientific & Industrial Research (PCSIR) Karachi, Aqueous neem leaf extract was prepared. only healthy, young male albino Wistar rats were included, weak elderly and female rats were not included in the experiment.

#### Participant Selection Strategy

80 rats of healthy young males were used.

#### Data Collection Techniques

Four groups of twenty (20) each were created at random from 80 male rats, labeled "A," "B," "C," and "D."

**Group A** labeled as the control group; it was only given a regular diet.

**Group B** received only Erythromycin via gastric gavage at a dosage of 100 mg/kg (body weight) for 14 days.

**Group C** was administered Erythromycin 100 mg/kg (body weight) and aqueous Neem Extract 500 mg/kg (body weight) simultaneously through gastric gavage.

**Group D** was administered only Aqueous Neem Extract 500 mg/kg (body weight) was administered through gastric gavages.

All of the rats were weighed at an electronic weighing machine before the start of the study and then repeated every third day. Rats were housed in plastic cages. Rats were weighed for final weights following the last dose and were given ether anesthesia before being placed in a glass container, given a midline longitudinal incision starting at the manubrium on the dissection board to reveal the organs, extend the sternum down to the lower abdomen.

All Rats' livers were excised and sliced into tiny specimens. For routine histological inspection under a light microscope, these slices were stained with Hematoxylin and Eosin. The gross weight of dissected rats of Group-A was measured at  $3.42 \pm 0.25$ , Group B measured  $5.38 \pm 0.67$ , Group C

was measured  $4.76 \pm 0.44$  and Group D was measured at  $3.41 \pm 0.22$

#### Micrometry

To analyze the morphometric changes micrometric measurements were used. The procedure was done with the help of an ocular micrometer scale and stage micrometer. To calibrate the ocular scale, a stage micrometer was used. The section of hepatic lobules under 10X, 40X, and 100X objective lenses were studied via a light microscope.

#### Statistical Analysis

SPSS (Statistical Package for Social Sciences) version 23 was used to analyze the given data. Arithmetic means were estimated for each quantitative variable, and results were presented as (Mean  $\pm$  SE) mean  $\pm$  standard error. ANOVA (post hoc Tukey's) was applied to measure significant differences between the groups. If the *P* value is equal to or less than 0.05, the result is considered significant with a 95% confidence interval.

#### Results

**Group A (control group)** The normal morphological and histological structure of the hepatic lobules is observed as shown in Figure with a diameter of hepatocytes of  $13.19 \pm 0.44 \mu\text{m}$  and a nuclear diameter was  $7.18 \pm 0.28 \mu\text{m}$  (Table-1 and Figure.7 & 8).

In Group B, the mean value of the diameter of hepatocyte per field in group B animals was  $16.54 \pm 0.6 \mu\text{m}$  (Table-1 and Figure.7). The hepatocyte diameter of group B animals was considerably increased ( $p < 0.01$ ) (Table-2) than that of group A animals due to ballooning and congestion as shown in (Figure.2 and 3). The mean nuclear diameter of group B animals was  $5.20 \pm 0.30 \mu\text{m}$  (Table-3) which is markedly reduced due to necrosis in hepatocytes as shown in (Figure.3 and 4). The statistics showed that the diameter of the nucleus of group B was

**Table-1: Mean Comparison of Hepatocytes Diameter  $\mu\text{m}$  of Albino Wistar Rats (Post Hoc Tukey's test)**

Group	Treatment	Mean $\pm$ SD
A (n=20)	Negative Control	$13.19 \pm 0.44$
B (n=20)	Treated	$16.54 \pm 0.61$
C (n=20)	Protected	$14.49 \pm 0.80$
D (n=20)	Positive Control	$13.0 \pm 0.52$

significantly reduced ( $p < 0.01$ ) than that of control group A (Table-4 and Figure-8).

The diameter of hepatocyte per field in group C was  $14.49 \pm 80 \mu\text{m}$ . Hepatocyte diameter was significantly increased ( $p < 0.01$ ) (Table-1) in group C animals when compared with the hepatocyte diameter of control group A but significantly reduced ( $p < 0.01$ ) hepatocyte diameter of group C animals when compared with the hepatocyte diameter of group B Animals (Table-2 and Figure.7).

The mean value of the diameter of the nucleus of

hepatocytes in group C animals was  $6.13 \pm 0.17 \mu\text{m}$ . The data displayed a significant reduction ( $p < 0.01$ ) in the diameter of the nucleus in group C in comparison with the nuclear diameter of control group A animal (Table-3 and Figure.8), but a significant increase ( $p < 0.01$ ) in the diameter of the nucleus in group C when compared with the nuclear diameter of group B animals due to hepatoprotective effect of Aqueous Neem Extract hepatocytes retains their architecture to some extent as shown in Figure.5.

The mean value of the diameter of hepatocyte per

**Table-2: Statistical analysis of the difference in hepatocyte diameter of Albino Wistar rats between different study groups**

Comparison	Statistical Comparison	Difference of Means	P-value
A vs B	Negative Control vs Treated	-3.35	<0.01*
A vs C	Negative Control vs Protected	-1.3	<0.01*
A vs D	Negative Control vs Positive Control	0.19	0.649
B vs C	Treated vs Protected	2.05	<0.01*
B vs D	Treated vs Positive Control	3.54	<0.01*
C vs D	Protected vs Positive Control	1.49	<0.01*

field in group D was  $13.0 \pm 0.52 \mu\text{m}$  as displayed in (Table-1) There was an insignificant decrease in the diameter of the hepatocyte of group D when compared with the hepatocyte diameter of group A animal, but a marked decrease of the hepatocyte diameter of group D in comparison with the

hepatocyte diameter of group B and group C (Table-2 and Figure.7). The mean nuclear diameter of group D animals was  $7.14 \pm 0.30 \mu\text{m}$  (Table 3). The data displayed an insignificant decrease in the diameter of the nucleus in group D animals when compared with the nuclear diameter of control group A, but a

**Table -3: Mean comparison of nuclear diameter  $\mu\text{m}$  of Albino Wistar Rats**

Group	Treatment	Nuclear Diameter Mean $\pm$ SD
A (n=20)	Negative Control	$7.18 \pm 0.28$
B (n=20)	Treated	$5.20 \pm 0.30$
C (n=20)	Protected	$6.13 \pm 0.17$
D (n=20)	Positive Control	$7.14 \pm 0.30$

significant increase ( $p < 0.01$ ) in the nuclear diameter of group D animals when compared with the nuclear diameter of group B and group C (Table-4, Figure.6 & 8).

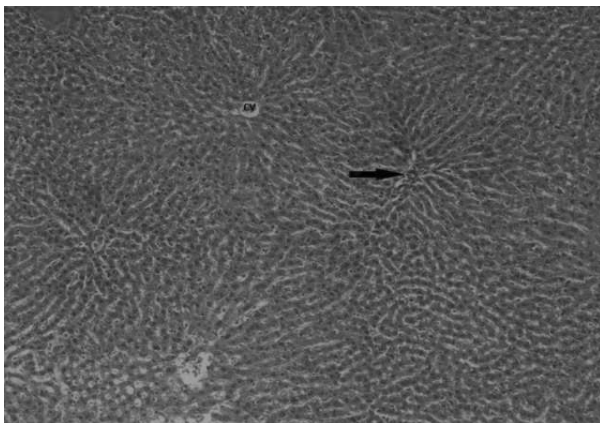
**Discussion**

Viral infection, drugs, alcohol usage, and hazardous chemical ingestion are all potential causes of liver injury. The majority of cases of liver damage are due to oxidative stress and redox imbalance in the human

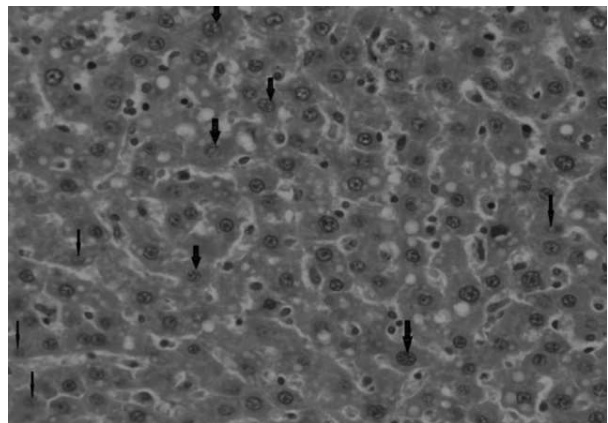
body.<sup>16</sup> Erythromycin is a macrolide antibiotic that has been used for many years to treat a variety of bacterial infections. Erythromycin acts as a bacteriostatic drug against a variety of gram-positive microorganisms, among other macrolides. Although clinically observed liver injury due to erythromycin use is infrequent, due to its prolonged usage, erythromycin has been identified as one of the leading causes of drug-induced liver injury.<sup>17</sup>

**Table -4: Statistical analysis of the difference in Nuclear diameter  $\mu\text{m}$  of Albino Wistar rats between different study groups**


Comparison	Statistical Comparison	Difference of Means	P-value
A vs B	Negative Control vs Treated	1.98	<0.01*
A vs C	Negative Control vs Protected	1.05	<0.01*
A vs D	Negative Control vs Positive Control	0.04	0.983
B vs C	Treated vs Protected	-0.93	<0.01*
B vs D	Treated vs Positive Control	-1.94	<0.01*
C vs D	Protected vs Positive Control	-1.01	<0.01*



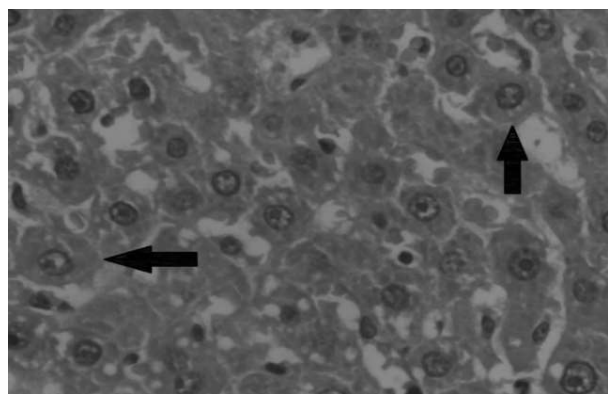
**Fig.1: Control Group A-100X (H&E) Histopathological Photograph of Group A (control) rats presenting normal hepatidobules, arrow represent portal triad**



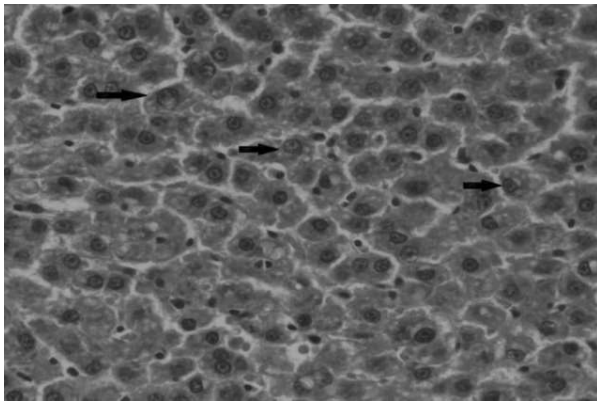
**Fig.2: Group B (Erythromycin Treated Rats)-400X (H&E) Histopathological Photograph presenting karyorrhexis (fragmentation of nucleus) thick arrows and karyolysis (fading of nucleus) thin arrows**



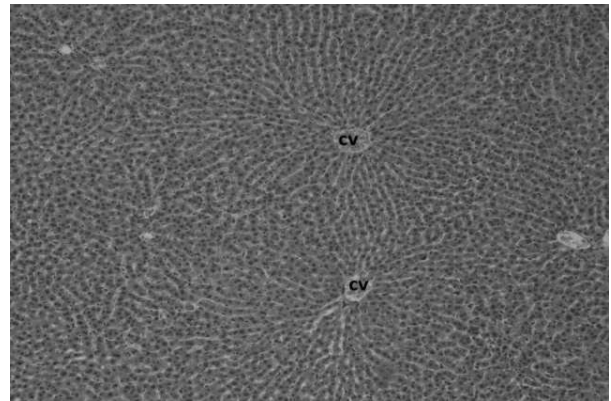
**Fig.3: Group B (Erythromycin Treated Rats)-400X (H&E) Histopathological Photograph Presenting ballooning of hepatocytes (arrow) and stars shows vacuolization**



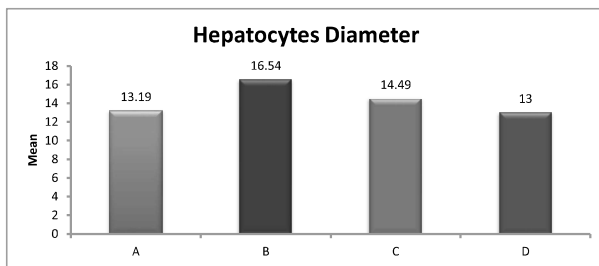
**Fig.4: Group B (Erythromycin Treated Rats)-1000X (H&E) Histopathological Photograph (H&E) presenting ballooning (arrows) of hypatocytes with nuclear changes and congestion**



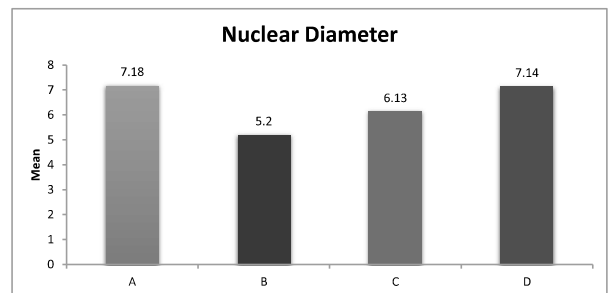
**Fig.5: Group C (Erythromycin and Neem Treated Rats)-400X (H&E) Histopathological Photograph (H&E-presenting slight increased hepatocytes diameter, and mild congestion**



**Fig.6: Group (Positive Control)-100X (H&E) Histopathological Photograph displayed normal architecture of liver with branching pattern hepatocytes around the central vein and portal triad appeared normal with no congestion and infiltration**



**Fig.7: Hepatocyte diameters of group A (no intervention group). Group B (Erythromycin Treated) hepatocyte diameters were markedly increased and in group C after Erythromycin and Neem Treatment hepatocyte diameters were decreased as compared to group B. Group D after the administration of neem Extract regained its normal dimensions as seen in control**



**Fig.8: Shows the nuclear diameters of group A (no intervention group). Group B (Erythromycin Treated) nuclear diameters were decreased. Group C nuclear diameters increased after Erythromycin and Neem Treatment as compared to group B. Group D after the Neem extract regained its normal nuclear dimensions**

Azadirachta indica has shown significant health benefits due to its huge antioxidant properties. Previous research has shown that Neem leaves and their constituents play a key role in the prevention of various diseases. The hepatoprotective effects of aqueous Neem extract were noted in albino Wistar rats and the study concluded that Neem leaves have an outstanding potential to perform as a hepatoprotective agent.<sup>18</sup> The current study is vital to assess the preventive effect of Neem leaf extract against erythromycin-induced hepatotoxicity in rats. In our present study, noticeable changes developed in albino rats treated with erythromycin for two weeks, resulting in hepatocellular damage which showed disturbed hepatocytes and nuclear

diameter. These remarkable changes were noticed in hepatocyte diameters, which was analogous to Ahmed I et al. study found that erythromycin caused central necrosis, increased hepatocyte diameter, and decreased nuclear diameter when administered in large dosages over a period of time.<sup>19</sup> P. Singh et al. study also matched that this could be due to oxidative stress and free radical production caused by erythromycin. Hepatocellular necrosis with marked lobular inflammation of many plasma cells with lymphocytes and eosinophils was noted.<sup>20</sup> In addition, microvesicular steatosis with small lipid droplets and hyperchromatic nuclei was seen in the cytoplasm of the hepatocytes. Likewise, Milos et al. described the mechanism of liver injury caused by

erythromycin and explained how the hepatocyte's diameters increased with decreased nuclear diameter due to disruption of mitochondrial oxidation.<sup>21</sup> This is in accordance with Abdel et al. who documented that hepatitis, cholestasis, and changes in hepatocyte diameters that signified hepatocellular damage occurred in laboratory rats treated with erythromycin.<sup>22</sup>

Furthermore, changes in hepatocytes and nuclear diameters, mononuclear infiltration, edematous degeneration, and zone 3 significant necrosis related to erythromycin toxicity were found by Kamath P et al. Erythromycin's long-term usage resulted in sinusoidal dilatation and hypertrophy of hepatocytes in the animal rat's liver.<sup>23</sup> These findings concurred with those of Anne M. Larson et al. who identified characterized comparable diameter changes in hepatocytes. In contrast to erythromycin-treated rats, animals administered erythromycin plus aqueous neem leaf extract had remarkably less necrotic, pyknotic, and nuclear diameter changes in their liver tissue.<sup>24</sup>

Many neem leaf constituents, such as nimbidin have anti-inflammatory activity and help in restoring hepatocyte diameter to its normal size.<sup>25</sup> Hemdan BA et al. also utilized the same dosage of *A. indicia* leaf extract in their study. In this example, aqueous neem extract had a hepatoprotective effect, restoring the liver's damaged architecture to its normal structure with normal hepatocyte diameters. The scientists came to the conclusion that quercetin in neem leaves has antioxidant properties, raising intracellular glutathione concentrations and preventing lipid peroxidation by scavenging free radicals.<sup>26</sup> Faiza Aslam et al. did a similar study, indicating that neem leaf extract revealed hepatoprotective properties and practical usage of neem leaf in the regular system of medicine.<sup>27</sup> The antioxidant activity of neem leaves prevented erythromycin-induced hepatotoxicity. These findings suggest that aqueous neem extract reduced paracetamol-induced hepatotoxicity due to its high flavonoid content, which contributed to the hepatoprotective effect via Neem leaves' anti-lipid peroxidation activity.<sup>28</sup> It agrees with research by IrmaSeriana et al. also observed that when rats were given neem extract and carbon tetrachloride, the

liver lobular architecture remained normal.<sup>29</sup>

The limitations of the study are the non-inclusion of a female group of animals and the liver functioning assessment, but the investigators have in plan in the next phase of research.

### Conclusion

Erythromycin was shown to have considerable hepatotoxic effects on albino Wistar rats in the current study. Aqueous Neem leaf extract (*Azadirachta indica*) significantly improved the necrotic changes of hepatocytes caused by Erythromycin. Aqueous Neem leaf extract is a potent antioxidant and hepatoprotective agent.

### Acknowledgment

I would like to thank Professor Kishwar Sultana and Dr. Sadia, senior scientific officer of (PCSIR), for their unwavering support during this study.

### REFERENCES

- Schulze RJ, Schott MB, Casey CA, Tuma PL, McNiven MA. The cell biology of the hepatocyte: A membrane trafficking machine. *Journal of cell biology*. 2019; 218: 2096-112. doi: 10.1083/jcb.201903090
- Messelmani T, Morisseau L, Sakai Y, Legallais C, Le Goff A, Leclerc E, et al. Liver organ-on-chip models for toxicity studies and risk assessment. *Lab on a Chip*. 2022; 22: 2423-50. doi: 10.1039/D2LC00307D
- Xu J, Kausalya PJ, Van Hul N, Caldez MJ, Xu S, Ong AG, et al. Protective functions of ZO-2/Tjp2 expressed in hepatocytes and cholangiocytes against liver injury and cholestasis. *Gastroenterology*. 2021; 160: 2103-18. doi: 10.1053/j.gastro.2021.01.027
- Bano N, Najam R. Histopathological and biochemical assessment of liver damage in albino Wistar rats treated with cytotoxic platinum compounds in combination with 5-fluorouracil. *Archives of Medical Science*. 2019; 15: 1092-103. doi: 10.5114/aoms.2019.86064
- Thompson WL, Takebe T. Human liver model systems in a dish. *Development, growth & differentiation*. 2021; 63: 47-58. doi: 10.1111/dgd.12708
- Doan T, Worden L, Hinterwirth A, Arzika AM, Maliki R, Abdou A, et al. Macrolide and nonmacrolide resistance with mass azithromycin distribution. *New England Journal of Medicine*. 2020; 383: 1941-50. doi: 10.1056/NEJMoa2002606
- Chávez AC, Comas LG, Espinosa LM, Lobo JY, de Provencs OC, Andrés JM. Impact of previous macrolide use on invasive pneumococcal disease due to erythromycin-resistant

- serotypes in adults over 59 years of age. *European Journal of Clinical Microbiology & Infectious Diseases*. 2022; 41: 227-34. doi: 10.1007/s10096-021-04368-2
8. Zhang H, Yin M, Li S, Zhang S, Han G. The Removal of Erythromycin and Its Effects on Anaerobic Fermentation. *International Journal of Environmental Research and Public Health*. 2022; 19: 7256. doi: 10.3390/ijerph19127256
  9. Al-Timimi ZK, Taher TA. Hepatotoxic Impact of Erythromycin Succinate After Orally Repeated Exposure in Male Albino Swiss Mice (*Mus musculus*). *The Iraqi Journal of Agricultural Science*. 2020; 51: 1375-80. doi: 10.36103/ijas.v51i5.1147
  10. Borkatulla B, Ferdous J, Uddin AH, Mahmud P. Bangladeshi medicinal plant dataset. *Data Brief*. 2023; 48: 109211. doi: 10.1016/j.dib.2023.109211
  11. Altayb HN, Yassin NF, Hosawi S, Kazmi I. In-vitro and in-silico antibacterial activity of *Azadirachta indica* (Neem), methanolic extract, and identification of Beta-D-Mannofuranoside as a promising antibacterial agent. *BMC plant biology*. 2022; 22: 262. doi: 10.1186/s12870-022-03650-5
  12. Prasathkumar M, Anisha S, Dhriysya C, Becky R, Sadhasivam S. Therapeutic and pharmacological efficacy of selective Indian medicinal plants – A review. *Journal of Medicinal Plants*. 2021; 1: 10-29. doi: 10.1016/j.phyflu.2021.100029.
  13. Jose Francisco Islas, Ezeiza Acosta, Zuca G-Buentello. An overview of Neem (*Azadirachta indica*) and its potential impact on health. *Journal of Functional Foods*. 2020; 74: 104171. doi: 10.1016/j.jff.2020.104171
  14. Sarkar S, Singh RP, Bhattacharya G. Exploring the role of *Azadirachta indica* (neem) and its active compounds in the regulation of biological pathways: an update on molecular approach. *3 Biotech*. 2021; 11: 178. doi: 10.1007/s13205-021-02745-4
  15. Morris J, Gonzales CB, De La Chapa JJ, Cabang AB, Fountzilias C, Patel M, et al. The highly pure neem leaf extract, SCNE, inhibits tumorigenesis in oral squamous cell carcinoma via disruption of pro-tumor inflammatory cytokines and cell signaling. *Frontiers in oncology*. 2019; 9: 890. doi: 10.3389/fonc.2019.00890
  16. Alzohairy MA. Therapeutics role of *Azadirachta indica* (Neem) and their active constituents in diseases prevention and treatment. *Evidence-Based Complementary and Alternative Medicine*. 2016; 2016: 7382506. doi: 10.1155/2016/7382506
  17. Rotundo L, Pyrsopoulos N. Liver injury induced by paracetamol and challenges associated with intentional and unintentional use. *World journal of hepatology*. 2020; 12: 125-36. doi: 10.4254/wjh.v12.i4.125
  18. Wang B, Nam S, Kim E, Jeon H, Lee K, Xie K. Identification of Erythromycin and Clarithromycin Metabolites Formed in Chicken Liver Microsomes Using Liquid Chromatography-High-Resolution Mass Spectrometry. *Foods*. 2021; 10: 1504. doi: 10.3390/foods10071504
  19. Hameed F, Khan Ms, Imran S, Sadiq Ma, Sair M, Adil R. Hepatoprotective role of *Azadirachta Indica* and Vitamin E in acetaminophen induced liver toxicity in Wistar rats on the basis of liver enzyme. *Pakistan Journal of Medical Health Sciences*. 2021; 15: 2330-32. doi: 10.53350/pjmhs211592330
  20. Edhi AI, Hakim S, Shams C, Bedi D, Amin M, Cappell MS. Clarithromycin-associated acute liver failure leading to fatal, massive upper gastrointestinal hemorrhage from profound coagulopathy: case report and systematic literature review. *Case Reports in Hepatology*. 2020; 2020: 2135239. doi: 10.1155/2020/2135239
  21. Singh P, Singh L, Mondal SC, Kumar S, Singh IN. Erythromycin-induced genotoxicity and hepatotoxicity in mice pups treated during prenatal and postnatal period. *Fundamental & Clinical Pharmacology*. 2014; 28: 519-29. doi: 10.1111/fcp.12055
  22. Mihajlovic M, Vinken M. Mitochondria as the Target of Hepatotoxicity and Drug-Induced Liver Injury: Molecular Mechanisms and Detection Methods. *International Journal of Molecular sciences*. 2022; 23: 3315. doi: 10.3390/ijms23063315
  23. Abdel-Daim MM. Pharmacodynamic interaction of *Spirulina platensis* with Erythromycin in Egyptian Baladi bucks (*Capra hircus*). *Small Ruminant Research*. 2014; 120: 234-41. doi: 10.1016/J.SMALLRUMRES.2014.05.013
  24. Kamath P, Kamath A, Ullal SD. Liver injury associated with drug intake during pregnancy. *World Journal of Hepatology*. 2021; 13: 747-62. doi: 10.4254/wjh.v13.i7.747
  25. Batra N, Kumar VE, Nambiar R, De Souza C, Yuen A, Le UR, et al. Exploring the therapeutic potential of Neem (*Azadirachta Indica*) for the treatment of prostate cancer: a literature review. *Annals of Translational Medicine* 2022; 10: 754. doi: 10.21037/atm-22-94
  26. 3Hemdan BA, Mostafa A, Elbatanony MM, El-Feky AM, Paunova-Krasteva T, Stoitsova S, et al. Bioactive *Azadirachta indica* and *Melia azedarach* leaves extracts with anti-SARS-CoV-2 and antibacterial activities. *Plos one*. 2023; 18: e0282729. doi: 10.1371/journal.pone.0282729
  27. Aslam F, Jamil S, Aslam MA. Antihepatotoxic Activity of Gemmotherapeutically treated Neem and alcoholic extract



- of Neem in Albino Rats. Pakistan Journal of Medical and Health Sciences. 2016; 10: 68-76.
28. Yarmohammadi F, Mehri S, Najafi N, Salar Amoli S, Hosseinzadeh H. The protective effect of *Azadirachta indica* (neem) against metabolic syndrome: A review. Iran Journal Basic Medical Sciences. 2021; 24: 280-92. doi: 10.22038/ijbms.2021.48965.11218
29. Seriana I, Akmal M, Darusman D, Wahyuni S, Khairan K, Sugito S. Neem leaf (*Azadirachta indica* A. Juss) ethanolic extract on the liver and kidney function of rats. The Scientific World Journal. 2021; 2021: 7970424. doi: 10.1155/2021/7970424

#### Authors Contribution

**NJ:** Idea conception, study designing, data collection, data analysis, results and interpretation

**IR:** Data analysis, results and interpretation, manuscript writing, and proofreading

**MR:** Manuscript writing, and proofreading

**NJ:** Data analysis, results and interpretation

**AR:** Manuscript writing, and proofreading

**LF:** Data collection